

## CORRELATION BETWEEN ULTRASOUND FINDINGS AND MOLECULAR SUBTYPES OF BREAST CANCER

*Rahma Mohammed Abed Alghazal, Eman Soliman Metwally and Ali Haggaa Ali*

---

### ABSTRACT:

Department of Radiology, Faculty of Medicine, Ain Shams University

**Corresponding author:**

Rahma Mohammed Abd Alghazal;

**Mobile:** +9647700519009

**E.mail:**

rahmaalghazal3@gmail.com

Received: 14/9/2021

Accepted: 12/10/2021

**Online ISSN: 2735-3540**

**Background:** Breast cancer is the most common malignant tumor and the major cause of death among women worldwide. Molecular subtyping of breast cancer is important to individualize its management, to understand prognosis of disease and avoid overtreatment.

**Aim of Study:** The current study aimed at correlating the breast cancer subtypes with their different ultrasound criteria. The ultrasound findings might have an important role in predicting different groups.

**Patients and Methods:** The current study is a retrospective study. Which was conducted on 40 females patients with breast cancer; during the period from November 2020 till March 2021. The age were 45-65 years old. They were presented to the Radiology Department, Ain-Shams University, Faculty of Medicine. The selected cases had been afforded from: the Breast-unit of General Surgery Hospital, El Demerdash University Hospital,, Clinical Oncology & Nuclear Medicine Department.

**Results:** When analyzing the main four breast cancer subtypes in the current work we found that the rates of Luminal A was 34%, Luminal B was 40%, HER2 was 15%, and TNBC was 11%. LA subtype was strongly associated with hypoechoic lesions showing irregular shape, speculated margin surrounded by desmoplastic reaction with posterior shadowing. LB subtype was associated with irregular shape and speculated margin with absence of desmoplastic reaction.

Human Epidermal Growth Factor (HER2) subtype in the current study was found to be associated with irregular shape, lobulated margin, absent desmoplastic reaction with posterior acoustic mixed shadowing and enhancement. This could be related to suspicious microcalcifications. Triple Negative Breast Cancer (TNBC) lesions in the present work were predominantly oval in shape with circumscribed margin; the benign looking malignant lesions which carry the worst prognosis. Based on the latter finding, the good radiologist should be aware about ultrasound features of different molecular subtype in order not to under diagnose a malignant breast lesion.

**Conclusion:** The sonographic features as margin, shape, posterior acoustic features were significantly associated with molecular subtypes. The histopathological grade and hormone receptor status. Being able to predict the molecular subtype. The current study recommend that the radiologist should be aware about different imaging features of different molecular subtypes especially

*the triple negative breast cancer which had the most benign looking criteria aiming for better lesion characterization and to allow the patient to benefit from earlier non-invasive, cheap diagnosis and the curable on time treatment.*

**Keywords:** Breast cancer, ultrasound features, Molecular subtypes.

---

## **INTRODUCTION:**

Cancer Breast is a heterogeneous and complex disease with different morphologic, biologic, and molecular features. The histopathological characteristics of tumors had been used to determine the management of breast cancer. However they do not provide sufficient information due to tumor heterogeneity<sup>(1,2&3)</sup>.

Distinct molecular subtypes of breast cancer had been defined based on gene expression. Molecular subtyping of breast cancer is essential to individualize its management, to understand prognosis of disease and avoid overtreatment<sup>(4)</sup>.

Ultrasonographic imaging features of breast cancer, including the tumor shape, margin, boundaries, posterior features, multiplicity, orientation, and calcification, are significant predictive sonographic signs of different molecular subtypes<sup>(5)</sup>.

Previous literatures had indicated an excellent improvement in U/S technologies. It would be possible to have highly sensitive machines be able to differentiate malignant solid breast masses from benign ones based on their different U/S criteria<sup>(6)</sup>.

Many studies correlated the ultrasonography features of malignant lesions with their grade, while limited studies discussed the correlation with molecular subtypes of breast cancer. Overlap of benign and malignant ultrasound morphology descriptors still represents a challenge to breast imaging radiologists. Knowing the descriptors of the different molecular subtypes may help radiologists to

decrease both false positive and false negative diagnosis<sup>(3,5,6)</sup>.

---

## **AIM OF THE WORK:**

The present study aimed at detecting the correlation between ultrasound morphological features and different molecular subtypes of breast cancer which could increase the diagnostic ultrasound accuracy.

---

## **PATIENTS AND METHODS:**

The current study is a retrospective study. Which was conducted on female patients with breast cancer. They were presented to the Radiology Department, Ain-Shams University, Faculty of Medicine. The selected cases had been afforded from: The Breast-unit of General Surgery Hospital, El Demerdash University Hospital, Clinical Oncology & Nuclear Medicine Department.

- Number of patients: 40 female patients had breast cancer.
- Time: during the period from November 2020 till March 2021.
- Age: 45-65 years old  $\pm$  10.58

An informed consent explaining the procedure details was obtained from all patients prior to inclusion in this study. The study was conducted according to the stipulations of the ASU ethical and scientific committee. The privacy of participants and confidentiality of data were guaranteed during the various phases of the study. The inclusion criteria were: Female patients with

breast cancer, only the exclusion Criteria were:

- a) History of neoadjuvant therapy;
- b) Ductal carcinoma in situ;
- c) Patients had started any local or systemic therapy.

#### **Study methods:**

Forty female patients had breast cancers were selected for the present study the inpatient wards as well as outpatient clinic were admitted for bilateral Sonomammographic examination. An U/S device; GE (Pristima), Siemens (Mammomat 1000) & Samsung (Accuvix XG) machines in Ain Shams University Medical Hospital. A linear probe of 9-15 MHz was used.

The technique was done after exposure of the breast with the patient lying supine and her ipsilateral hand raised above the head the U/S probe was oriented perpendicular to the chest wall. Radial scanning technique, in a clockwise fashion wising the nipple as a center point wall followed. Scanning of each breast quadrant in the sagittal and transverse planers were performed. Scanning axially lymph nodes.

The examination time took about 20 minutes. All the real-time scanning was performed by a radiologist with at least 5 years of experience in breast U/S. More experienced radiologist with at least 7-10 years' experience rechecked the findings. As a way of a double-blind analysis. The final interpretation and diagnosis were obtained.

#### **Histopathologic diagnosis, Image analysis and interpretation of Conventional Itrasound:**

U/S guided biopsy was scheduled for patients with suspicious breast lesions. The procedure was performed by at least 7-10 years experienced radiologist. Biopsy was taken under complete aseptic condition. Sterilization of the area of interest with

betadine was done; the latter was followed by sterilization the U/S probe. The radiologist used sterile gloves and injected a local anesthesia followed by introduction of the Tru-cut needle. The needle under ultrasound guidance targeted the lesion. At least four core biopsies were taken.

Tissues biopsied were sent to the Pathology Department. The tissues were formalin fixed, paraffin embedded and subsequently used for IHC staining with appropriate antibodies to detect the hormonal status of the lesions (ER, PR, HER2 gene expression and Ki-67). The cutoff point for ER-positive, PR-positive expression was 10%. HER-2 status was graded as 0, 1+, 2+ and 3+. The HER-2 status of 3+ was deemed to be positive, while statuses of 0 and 1+ were deemed to be negative. Fluorescence in situ hybridization (FISH) was performed on all grade 2 samples. Samples with a > 2-fold-change in expression were regarded as negative. Samples with a < 2-fold increase were regarded as positive for gene amplification. Ki67 was visually scored for the percentage of tumor cell nuclei with positive immunostaining above background. Over **Histopathologic diagnosis** by following and receiving the pathology report from the patient.

#### **Statistical analysis:**

Recorded data were analyzed using the statistical package for social sciences, version 20.0 (SPSS Inc., Chicago, Illinois, USA). Quantitative data were expressed as mean± standard deviation (SD). Qualitative data were expressed as frequency and percentage.

*The following tests were done:* Chi-square ( $\chi^2$ ) test of significance was used in order to compare proportions between qualitative parameters. The confidence interval was set to 95% and the margin of error accepted was set to 5%. So, the p-value was considered significant as the following:

Probability (P-value). P-value  $\leq 0.05$  was considered significant. P-value  $\leq 0.001$  was considered as highly significant. P-value  $> 0.05$  was considered insignificant.

analysis of the main four breast cancer subtypes of the current work among the patients showed the following figures:

- LA: 34% i.e. 14 patients.
- LB: 40% i.e. 16 patients.
- TNBC: 11% i.e. 4 patients.
- HER2: 15% i.e. 6 patients.

**RESULTS:**

The current study comprised 40 female patients with cancer breast. The resulting

Table (1): Showing age, U/S criteria of LA subtype :

		n	Row%	Column%	P value
Age groups	$\leq 50$ yrs	8	33.3%	55.9%	0.429
	$> 50$ yrs	6	34.9%	44.1%	
Density	Fatty	8	33.9%	55.9%	0.832
	Fibroglandular	6	34.1%	44.1%	
Shape	Oval	2	15.4%	11.8%	$< 0.001$
	Irregular	12	40.5%	88.2%	
Margin	Circumscribed	2	13.3%	5.9%	
	Lobulated	4	20.0%	17.6%	
	Speculated	8	47.3%	76.5%	
Echogenicity	Hyper				0.713
	Iso	2	27.8%	14.7%	
	Hypo	12	35.4%	85.3%	
E S M	Enhancement	2	18.2%	11.8%	
	Shadowing	10	51.1%	70.6%	
	Mixed	2	19.4%	17.6%	
Number of lesion	Single	10	33.8%	64.7%	0.219
	Multiple	4	34.3%	35.3%	
Calcification	No	8	30.6%	55.9%	0.025
	Yes	6	39.5%	44.1%	
Size grouped	$< 2$	10	38.3%	52.9%	0.036
	$\geq 2$	4	30.2%	47.1%	
Surrounding parenchyma	No	10	32.4%	67.6%	0.613
	Yes	4	37.9%	32.4%	
Desmoplastic reaction	No	5	22.1%	44.1%	$< 0.001$
	Yes	9	59.4%	55.9%	

***Correlation Between Ultrasound Findings And Molecular Subtypes Of Breast Cancer***

Table (2): Showing age, U/S criteria of LB subtype :

		n	Row %	Column %	P value
Age groups	<=50 yrs	10	40.4%	60.5%	
	>50 yrs	6	34.9%	39.5%	0.429
Density	Fatty	10	41.1%	60.5%	
	Fibroglandular	6	34.1%	39.5%	0.832
Shape	Oval	5	34.6%	23.7%	
	Irregular	11	39.2%	76.3%	<0.001
Margin	Circumscribed	2	40.0%	15.8%	
	Lobulated	4	33.3%	26.3%	
	Speculated	10	40.0%	57.9%	
Echogenicity	Hyper				
	Iso	2	33.3%	15.8%	
	Hypo	14	39.0%	84.2%	0.713
E S M	Enhancement	2	36.4%	21.1%	
	Shadowing	10	34.0%	42.1%	
	Mixed	4	45.2%	36.8%	
Number of lesion	Single	14	38.5%	65.8%	
	Multiple	2	37.1%	34.2%	0.219
Calcification	No	11	46.8%	76.3%	
	Yes	5	23.7%	23.7%	0.025
Size grouped	<2	8	40.4%	50.0%	
	>=2	8	35.8%	50.0%	0.036
Surrounding parenchyma	No	11	40.8%	76.3%	
	Yes	5	31.0%	23.7%	0.613
Desmoplastic reaction	No	10	41.2%	73.7%	
	Yes	6	31.3%	26.3%	<0.001

Table (3): Showing age, U/S criteria of TNBC subtype :

		n	Row %	Column %	P value
Age groups	<=50 yrs	1	15.8%	69.2%	0.429
	>50 yrs	3	9.3%	30.8%	
Density	Fatty	2	10.7%	46.2%	0.832
	Fibroglandular	2	15.9%	53.8%	
Shape	Oval	3	34.6%	69.2%	<0.001
	Irregular	1	5.4%	30.8%	
Margin	Circumscribed	3	46.7%	53.8%	
	Lobulated	0	13.3%	30.8%	
	Speculated	1	3.6%	15.4%	
Echogenicity	Hyper				0.713
	Iso	1	16.7%	23.1%	
	Hypo	3	12.2%	76.9%	
E S M	Enhancement	2	31.8%	53.8%	
	Shadowing	1	6.4%	23.1%	
	Mixed	1	9.7%	23.1%	
Number of lesion	Single	4	16.9%	84.6%	0.219
	Multiple	0	5.7%	15.4%	
Calcification	No	3	14.5%	69.2%	0.025
	Yes	1	10.5%	30.8%	
Size grouped	<2	3	17.0%	61.5%	0.036
	>=2	1	9.4%	38.5%	
Surrounding parenchyma	No	4	14.1%	76.9%	0.613
	Yes	0	10.3%	23.1%	
Desmoplastic reaction	No	4	17.6%	92.3%	<0.001
	Yes	0	3.1%	7.7%	

**Correlation Between Ultrasound Findings And Molecular Subtypes Of Breast Cancer**

Table (4): Showing age, U/S criteria of HER2 subtype :

		n	Row %	Column %	P value
Age groups	<=50 yrs		15.8%	69.2%	
	>50 yrs	6	9.3%	30.8%	0.429
Density	Fatty	4	10.7%	46.2%	
	Fibroglandular	2	15.9%	53.8%	0.832
Shape	Oval	1	34.6%	69.2%	
	Irregular	5	5.4%	30.8%	<0.001
Margin	Circumscribed	0	46.7%	53.8%	
	Lobulated	5	13.3%	30.8%	
	speculated	1	3.6%	15.4%	
Echogenicity	Hyper				
	Iso	2	16.7%	23.1%	
	Hypo	4	12.2%	76.9%	0.713
E	Enhancement	3	31.8%	53.8%	
S	Shadowing	1	6.4%	23.1%	
M	Mixed	2	9.7%	23.1%	
Number of lesion	Single	2	16.9%	84.6%	
	Multiple	4	5.7%	15.4%	0.219
Calcification	No	2	14.5%	69.2%	
	Yes	4	10.5%	30.8%	0.025
Size grouped	<2	1	17.0%	61.5%	
	>=2	5	9.4%	38.5%	0.036
Surrounding parenchyma	No	4	14.1%	76.9%	
	Yes	2	10.3%	23.1%	0.613
Desmoplastic reaction	No	5	17.6%	92.3%	
	Yes	1	3.1%	7.7%	<0.001

Table (5): showing the histopathological results and grade in different molecular subtypes.

LA subtype: For 14 patients.

		n	Row%	Column%	P value
Pathology	IDC	12	29.9%	76.5%	
	ILC	2	61.5%	23.5%	
Grade	1	12	43.9%	73.5%	
grouped	2	2	20.9%	26.5%	0.050

LB subtype: For 16 patients.

		n	Row%	Column%	P value
Pathology	IDC	38	39.1%	89.5%	
	ILC	2	30.8%	10.5%	
Grade	1	22	35.1%	52.6%	
	grouped	2	18	41.9%	47.4%

TNBC subtype: For 4 patients.

		n	Row%	Column%	P value
Pathology	IDC	3	13.8%	92.3%	
	ILC	1	7.7%	7.7%	
Grade	1	1	7.0%	30.8%	
	grouped	2	3	20.9%	69.2%

HER2 subtype: For 6 patients.

		n	Row%	Column %	P value
Pathology	IDC	6	17.2%	100.0%	
	ILC	0	0.0%	0.0%	
Grade	1	4	14.0%	53.3%	
	grouped	2	2	16.3%	46.7%

**Luminal A breast cancer case presentation:**

52-year-old female patient presented, symptomless, was coming for screening.

Family history of breast cancer: positive.

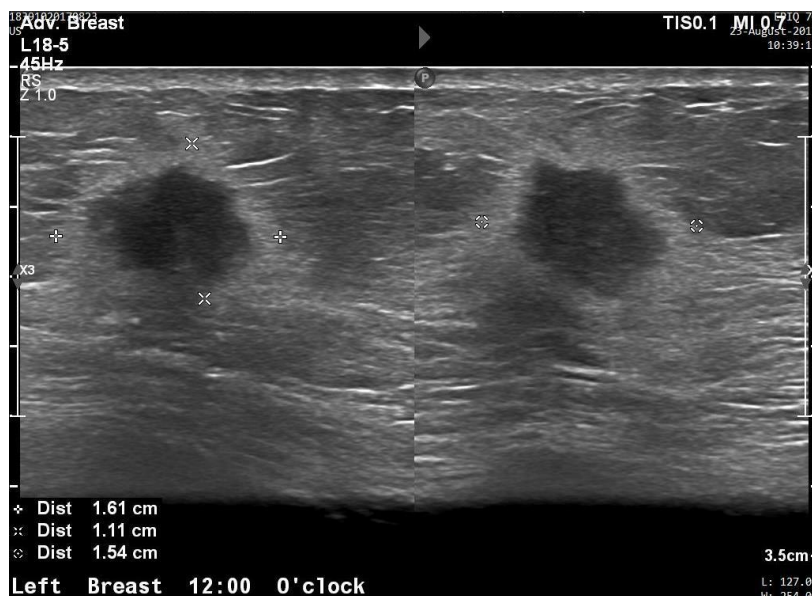


Fig. (1): U/S showing hypoechoic lesion, irregular in shape with spiculated margin. Measuring 1.6x1.1cm in its maximum dimensions surrounded by desmoplastic reaction and showing posterior acoustic shadowing.



**Histopathological examination result:**

Invasive ductal carcinoma grade II.

**Immunohistochemical revealed:**

ER: positive.

PR: positive.

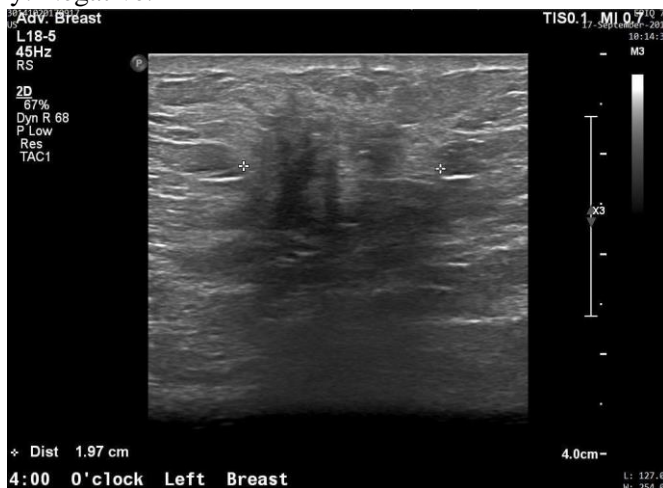HER2: negative.

Ki-67: 2%.

**Luminal B HER2 –ve breast cancer case presentation:**

58-year-old female patient presented with right breast lump.

Family history: Negative.



**Fig. (2):** U/S of fibroglandular breast showing hypoechoic irregular lesion with speculated margin. Measuring 2cm in its maximum dimension not surrounded by desmoplastic reaction with posterior acoustic shadowing. The parenchyma showed mild distortion.

**Histopathological examination result:**

Invasive ductal carcinoma grade II.

**Immunohistochemistry revealed :**

ER: positive.

PR: negative.

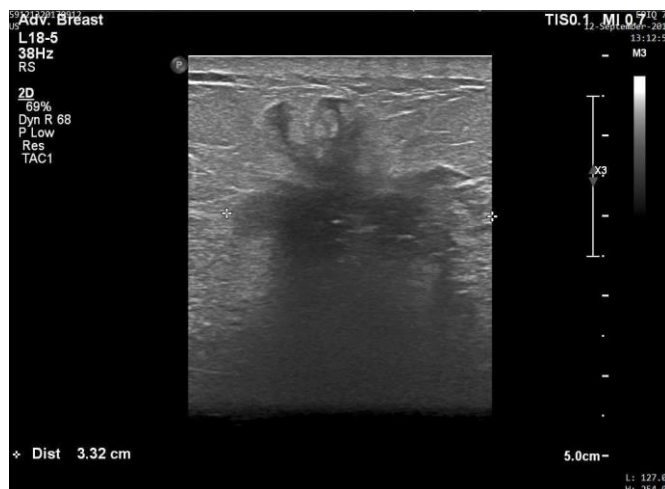
HER2: negative

Ki-67: 50%.

**Luminal B HER2 –ve breast cancer case presentation:**

65-year-old female patient presented with right breast mass.

Family history: Positive.



**Fig. (3):** U/S breast showing irregular shaped lesion with speculated margin measuring 3.3 cm in its maximum dimensions showing posterior acoustic shadowing.

**Histopathological examination result:**

Invasive duct carcinoma grade II.

**Immunohistochemistry revealed:**

ER: positive.

PR: negative.

HER2: negative.

Ki-67: 50%

**Luminal B HER2 +ve breast cancer case presentation:**

60-years-old female patient presented with left breast lump.

Family history: Negative.

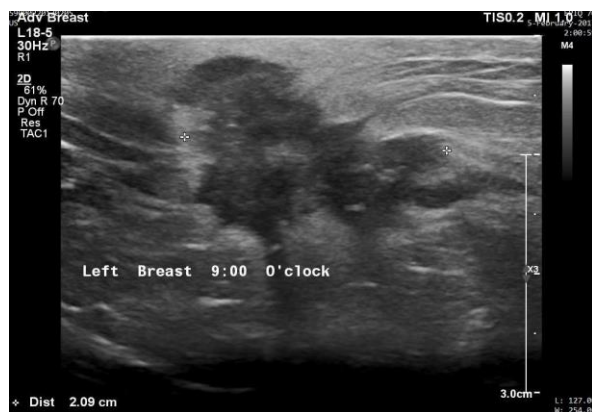

Fig. (4): U/S of fibroglandular breast showing hypoechoic focal lesion, irregular in shape with speculated margin is not surrounded by desmoplastic reaction, mixed posterior acoustic shadowing and enhancement. The parenchyma showed distortion and few calcific foci.

**Histopathological examination result:**

Invasive duct carcinoma grade III.

**Immunohistochemical results revealed:**

ER: positive.

PR: negative.

HER2: positive.

Ki-67: 30%.

**Triple Negative Breast Cancer case presentation:**

47-years-old female patient presented with left breast mass.

Family history: Negative.

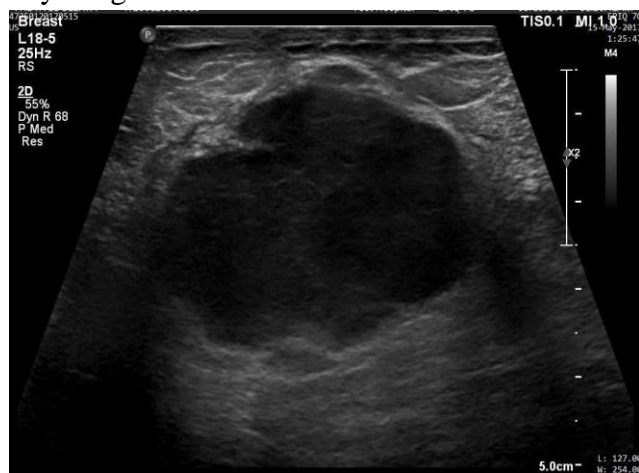

Fig. (5): U/S showed fibroglandular breast with hypoechoic oval shaped lesion with circumscribed margin. Measuring 4.3x3.6cm in its maximum dimensions showing posterior acoustic enhancement with edge attenuation. The lesion is not surrounded by desmoplastic reaction.

**Histopathological examination result:**

Invasive ductal carcinoma grade III.

**Immunohistochemistry results:**

ER: negative.

PR: negative.

HER2: negative.

Ki-67: 30%

**Triple Negative Breast Cancer case presentation:**

45-year-old female patient presented with right breast mass.

Family history: Negative.

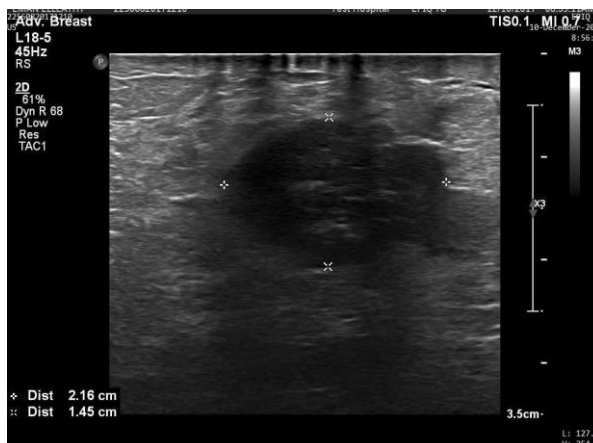


Fig. (6): U/S breast showing hypoechoic oval shaped lesion with circumscribed margin. Measuring 2.2x1.5cm in its maximum dimensions showing mixed posterior acoustic shadowing and enhancement. The lesion is not surrounded by desmoplastic reaction. No associated parenchymal distortion or calcification noted.

**Histopathological examination result:**

Invasive ductal carcinoma grade III.

**Immunohistochemistry results:**

ER: negative.

PR: negative.

HER2: negative.

Ki-67: 50%.

**HER2 breast cancer case presentation:**

58-years-old female patient presented with left breast lump.

Family history: Negative.

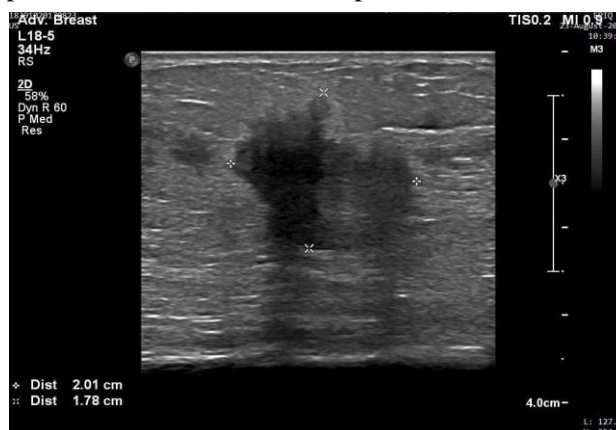


Fig. (7): U/S of breast showing hypoechoic irregular shaped lesion with speculated margin measuring 2x1.8cm in its maximum dimensions showing mixed posterior acoustic shadowing and enhancement. The lesion is not surrounded by desmoplastic reaction. Another hypoechoic small satellite lesion was noted near the lesion.

**Histopathological examination result:**

Invasive lobular carcinoma grade III.

**Immunohistochemistry revealed:**

ER: negative.

PR: negative.

HER2: positive.

**HER2 breast cancer case presentation:**

52-years-old female patient presented with right breast lump.

Family history: Positive.

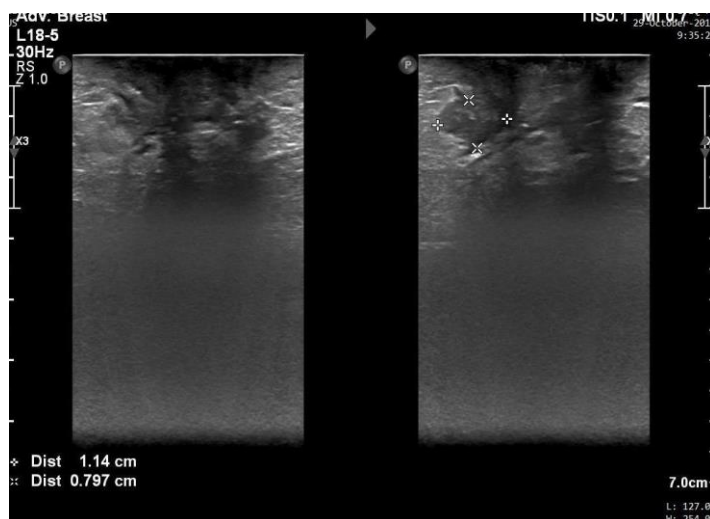


Fig. (8): U/S of breast showing hypoechoic irregular shaped lesion .The lesion was associated with parenchymal distortion and other satellite lesions. The largest measuring 1.2 cm in its maximum dimension.

**Histopathological examination result:**

Invasive ductal carcinoma grade III.

**Immunohistochemistry revealed:**

ER: negative.

PR: negative.

HER2: positive.

---

**DISCUSSION:**

The present study aimed at correlating different U/S criteria of histopathological proven malignant breast cancer with their molecular subtyping for better lesion characterization.

The current study comprised 40 female patients with breast cancer. When analyzing the main four breast cancer subtypes. The present results showed the percentage rates of the subtypes as: LA 34%, LB 40%, HER2 15%, and TNBC 11%.

The result of the present work showed LB subtype represented 40% and the cases

followed by LA subtype 34%. While <sup>(6)</sup> (2015) in their study showed that LA subtype was 37.8% and LB subtype was 36.8%.

The differences between the current work and <sup>(6)</sup> (2015) did not rank to valuable statistical difference.

The mean age of the patients was 50 +/- 10 with a range from 45 to 65 years. Correlation between each subtype with age and density had been done. The significance of the correlation of subtype of the lesion and density of the breast was related to the age groups.

## *Correlation Between Ultrasound Findings And Molecular Subtypes Of Breast Cancer*

Since dense fibroglandular breast was associated with younger age group and fatty breast was associated with older age group was described by <sup>(7)</sup>(2010).

In the present study, LA subtype included 14 patients with 8 patients

> 50 years and 6 patients <50 years. The result was not consistent with <sup>(8)</sup> (2015) study which had reported that most of LA patients' age was above 50 years.

LB subtype represented 16 patients of the current study with 10 patients >

= 50 years and 6 patients <50 years. The result was congruent with <sup>(8)</sup> (2015) which showed a higher percentage of the studied LB patients were less than 50 years of age.

HER2 subtype included 15 patients of our study with 6 patients > 50 years and 9 patients < 50 years. This was consistent with <sup>(6)</sup> (2015). They found that HER2 breast cancer lesions were significantly associated with advanced age.

TNBC subtype included 4 patients, 3 of them were > 50 years and one patient <50 years. Which indicates that TNBC was more associated with younger age group. The same results had been founded by <sup>(6)</sup> <sup>(9)</sup> (2015;2017) studies that showed the majority of TNBC lesions were encountered with younger age group.

In the present study, HER2 lesions were more encountered in fatty breast. However the rest of subtypes showed no significant predominance in a certain breast density. These findings were consistent with <sup>(8)</sup> (2015) findings that showed that HER2 subtype was significantly observed in postmenopausal women; but inconsistent in TNBC subtype. In the present work TNBC showed a strong association with dense fibroglandular breast.

Oval shaped lesions with circumscribed margin were found significantly associated with TNBC lesions (69% of the cases) ( $p < 0.001$ ) and least observed in LA lesions

where only 11% of them showed oval circumscribed margin. In contrast irregular shaped lesions were significantly observed in LA subtype (88% of the cases) with a P value  $< 0.001$ . In addition 76% of LB cases and 73% of HER2 cases were associated with irregular shape ( $P < 0.001$ ).

Speculated margin was observed in most of LA lesions (76% of the cases), while lobulated margin was more observed in HER2 lesions (66.7%). These findings were congruent with <sup>(10)</sup> <sup>(11)</sup> and <sup>(9)</sup> (2009;2013;2017) findings. They showed tumors with regular shape and circumscribed margins were more often triple negative breast cancer lesions showing hormone negativity while irregular shape and non-circumscribed margins was significantly associated with luminal tumors and hormone receptor positivity.

In the present study posterior shadowing was significantly associated with luminal tumors while posterior enhancement was found to be more observed with TNBC lesions (53%). Mixed enhancement and shadowing were associated with HER2 lesions which was observed in 53.3% of our HER2 cases.

These findings were consistent with <sup>(12)</sup> (2018) had stated that posterior enhancement is an eminent feature characterizing TNBC.

<sup>(13)</sup> (2020) findings were typically consistent with our study regarding the posterior acoustic shadowing feature in luminal subtypes. The current our results were not associated with <sup>(14)</sup> (2015) that showed that HER2 lesions were more associated with posterior enhancement.

Desmoplastic reaction was observed in LA lesions (55.5% of LA cases) with a P value  $< 0.001$ . Other subtypes showed no significant correlation with this criterion. Our finding was typically consistent with <sup>(6)</sup> & <sup>(9)</sup> (2015;2017) findings suggesting that desmoplastic reaction could denote slowly growing tumors.

All lesions were found to be more hypoechoic than isoechoic. Hyperechoic lesions were not found at all in all the examined masses. Hypoechoic was significantly associated with TNBC, a result that found to be consistent with the one reported by <sup>(13)</sup>(2020).

Multiplicity of the lesion was more frequently encountered in HER2 subtype lesions and was not significantly observed in other subtype. This is consistent with <sup>(13)</sup>(2020) that related this finding to the associated intraductal component that is found to be clearly associated with HER2+ receptor.

In the present study calcifications was found to be clearly encountered in HER2 subtype lesions (67%) with much less association with other subtype (P=0.025).

This was found to be in accordance with <sup>(15)</sup>(2011) and <sup>(16)</sup>(2018) showing that the expression of HER2 oncogene was strongly correlated with the presence of calcification upon ultrasound. Additionally <sup>(12)</sup>(2018) noticed that the presence of calcification was significantly associated with HER2+ status.

Associated parenchymal distortion was more observed in LA and HER2 subtypes. This was consistent with <sup>(16)</sup>(2018) study that showed that LB subtype was the least associated with architectural distortion. Intraductal extension in HER2 subtype might have a role in architectural distortion as stated by <sup>(13)</sup>(2020).

Tumors larger than 2 cm were frequently associated with HER2+ status. These included HER2 and LB HER2+ subtypes which both together constitute 33% of total number of cases (P=0.036). Smaller lesions were significantly seen in hormone receptor ER and /or PR positive breast masses. These results were correlated to the findings of <sup>(8)</sup>(2015)

TNBC lesions less than 2 cm were observed in one out of four patients, while the remaining three lesions were more than

or equal 2 cm, and these findings were not consistent with <sup>(16)</sup> and <sup>(8)</sup>(2018;2015). They showed that larger lesions were more associated with TNBC subtype. Invasive ductal carcinoma was the histopathological type the most common of breast cancer in the present study. Invasive lobular breast tumor was encountered in 23% of LA subtype's masses

### **Conclusion:**

The sonographic features as margin, shape, posterior acoustic features were significantly associated with molecular subtypes. The histopathological grade and hormone receptor status. Being able to predict the molecular subtype. The current study recommend that the radiologist should be aware about different imaging features of different molecular subtypes especially the triple negative breast cancer which had the most benign looking criteria aiming for better lesion characterization and to allow the patient to benefit from earlier non-invasive, cheap diagnosis and the curable on time management.

---

### **REFERENCES**

1. Irshad A, Leddy R, Pisano E, et al.,: Assessing the role of ultrasound in predicting the biological behavior of breast cancer. *AJR Am J Roentgenol* . 200:284–290, 2013.
2. Sung JS, Stamler S, Brooks J, Kaplan J, Huang T, Dershaw D, Lee CH, Morris; EA, Comstock CE : Breast cancers detected at screening MR imaging and mammography in patients at high risk: method of detection reflects tumor histopathological results. *Radiology* 280(3):716–722, 2016.
3. Sood R, Rositch AF, Shakoor D, et al.,: Ultrasound for breast cancer detection Globally: A systemic Review and Meta-Analysis .*Journal of Global Oncology*. 5:1-7, 2019.

### *Correlation Between Ultrasound Findings And Molecular Subtypes Of Breast Cancer*

4. Bombonatic A & Sgroi DC: The molecular pathology of breast cancer progression . The journal of pathology.;223(2):2018-18.2018.
5. Lamiaa M & Rania A: Role of Ultrasound in predicting molecular subtypes of invasive breast ductal carcinoma. Egyptian Journal of Radiology and Nuclear Medicine. 51:138-2020.
6. Zhang L, Li j, Xiao Y, Cui H., et al.,: Identifying Ultrasound and Clinical Features of Breast Cancer Molecular Subtypes by ensemble decision. SCI. Rep. 5, 11085; doi:10, 2015.
7. Willett AM, Michell MJ, Lee MJ, editors: Best Practice Diagnostic Guidelines for patients presenting with breast symptoms, 2010.
8. Celebi F, Pilancı K, Ordu C et al.,: The role of ultrasonographic findings to predict molecular subtype, histologic grade, and hormone receptor status of breast cancer. Diagn Interv Radiol; 21: 448–453, 2015.
9. Fletcher CD: Diagnostic Histo-pathology of Tumors: volume (2). Elsevier Health science. Mar. 2017.
10. Au-Yong IT, Evans AJ, Taneja S, Rakha EA, Green AR, PaishC, et al.,: Sonographic correlations with the new molecular classification of invasive cancer. Eur Radiol ;19:2342—8, 2009.
11. Larsen MJ, Kruse TA, Tan QH, et al. Classifications within molecular subtypes enables identification of BRCA1/BRCA2 mutation carriers by RNA tumor profiling. PLOS; 8:e64268, 2013.
12. Whitman GJ, Albarracin CT, Gonzalez-Angulo AM: Triple-negative breast cancer: what the radiologist needs to know. Semin Roentgenol. 46(1):26-39, 2018.
13. Jihyum kin, Doyeong Yu, Youngmee Kw et al.,: Genomic characteristics of Breast Cancer Nominate Molecular subtypes that predict chemotherapy response. Molecular Cancer Research; 19(3) 1541-1558, 2020.
14. Ko ES, Lee BH, Kim HA, Noh WC, Kim MS, Lee SA: Triple-negative breast cancer: correlation between imaging and pathological findings. Eur Radiol. 20 (5):1111-7, 2015.
15. Kojima Y, Tsunoda H: Mammography and ultrasound features of triple-negative breast cancer. Breast Cancer. 18(3):146-51, 2011.
16. Taneja S,Evans AJ,Rakha EA,Green AR, Ball G,Ellis I O: The mammographic correlations of a new immunohistochemical classification of invasive cancer. Cli 63:1228-3, 2018.

## علاقة المواصفات الشكلية في فحص الموجات فوق الصوتية لأنواع الفرعية الجزئية لسرطان الثدي

يعتبر سرطان الثدي الورم الخبيث الأكثر شيوعا والسبب الرئيسي للوفاة من السرطان بين النساء في جميع أنحاء العالم. ان تحديد النوع الفرعي الجزئي لسرطان الثدي هام لفهم تشخيص المرض وتجنب العلاج المفرط. على الرغم من أن التشخيص الهستوباثولوجي للأنسجة هو المعيار الذهبي للتمييز بين الأنواع الفرعية الجزئية لسرطان الثدي ، ولكنه أنه يعد مخترقا للجسم و يسبب عدم الراحة الجسدية للمرضى. تبعا لذلك ، لقد تطورت الطرق الغير المعتادة لتشخيص سرطان الثدي. أصبحت الموجات فوق الصوتية بمستوى عالي من السلامة وانخفاض التكلفة ، وهي الطريقة المفضلة للاطباء والمرضى. وقد تطورت في التقنيات للموجات فوق الصوتية و جعلت من الممكن التمييز بشكل كبير بين أورام الثدي الصلبة الخبيثة والحميدة اعتمادًا على معاييرها المختلفة للموجات فوق الصوتية.

وقد أجريت هذه الدراسة على السيدات التي تقدمت إلى قسم الأشعة ، بمستشفى عين شمس ومستشفى الدمرداش الجامعية لإجراء فحص على الثدي . المرضى الالتي وجد بثديهم كتلة مشتبه بها تم إجراء خزعة بالموجات فوق الصوتية. ثم تم إجراء الارتباط الفحصي التقني بين المواصفات الشكلية للكتلة في فحص الموجات فوق الصوتية وكل نوع فرعي جزئي و في النهاية شملت دراستنا ٤٠ مريض يعانون من سرطان الثدي. عند تحليل الأنواع الفرعية الاربعة الرئيسية لسرطان الثدي في الدراسة الحالية،

وجدت المعدلات كالتالي : LA:34% ;LB:40% ; HER2 15% TNBC 11%.

وقد ارتبط نوع الفرعي LA ارتباطا قويا بالشكل غير المنتظم ، محاطة بتفاعل مع تظليل خلفي. كما ارتبط النوع الفرعي LB بالشكل غير المنتظم والهامش المحيط مع عدم وجود تفاعل حول الورم. تم العثور على نوع فرعي HER2 في هذه الدراسة المرتبطة بالشكل غير المنتظم ظهرت الأورام TNBC في دراستنا ببيضاوية الشكل بشكل كبير مع هامش محدود . واستنادا إلى النتيجة الأخيرة ، يجب أن يكون أخصائي الأشعة الجيد على دراية بخصائص الموجات فوق الصوتية للنوع الفرعي الجزئي لكي ال يتم عدم تشخيص إصابة الثدي الخبيثة.

أظهرت الدراسة الحالية الأهمية الطبية لفحص الموجات فوق الصوتية للثدي بالوسائل الحديثة للتشخيص الدقيق وتحديد النوع الفرعي الجزئي لسرطان الثدي.