

ROLE OF SALINE INFUSION SONOHYSTEROGRAPHY AND TRANSVAGINAL COLOUR DOPPLER ULTRASONOGRAPHY IN EVALUATING UTERINE POLYPS: A PROSPECTIVE STUDY.

*Sarah Mohy El-Din AbdEl-Moniem**, *Samer Malak Botros***, and *Asmaa Magdy Salama***

ABSTRACT

Radiodiagnosis department, Al-Mokattam insurance hospital, t*.
Radiodiagnosis departement,
Ainshams university hospitals,
Cairo, Egypt**.

Corresponding author

Sarah Mohy El-Din AbdEl-Moniem

Mobile: + (2) 01092767707.

E.mail:

s_mohyology@yahoo.com

Received: 31/1/2022

Accepted: 27/2/2022

Online ISSN: 2735-3540

Background: Management of uterine polyps is primarily based on the hysteroscopy and biopsy.

Aim of the work: is to compare the diagnostic performance of transvaginal color Doppler sonography (TVCD) and sono-hysterography (SHG) in the diagnosis of endometrial polyps.

Patients and Methods: Thirty-four women (mean age, 38.6 years; range, 28–55 years) with clinical or B-mode sonographic suspicion of endometrial polyps were included in this prospective study. Transvaginal color Doppler sonography first and then SHG were performed in all patients. On TVCD, a polyp was suspected when a vascular pedicle penetrating the endometrium from the myometrium was identified. On SHG, a polyp was suspected when a focal polypoid lesion was seen within the endometrial cavity. All patients underwent hysteroscopy and endometrial biopsy, the findings of which were used as the criterion standard. Sensitivity and specificity for TVCD and SHG were calculated and compared by the McNemar test.

Results: Hysteroscopy and endometrial biopsy findings were as follows: 33 (97.1%) cases had endometrial polyps, while 4 (11.8%) had endometrial hyperplasia, 6 (17.6%) had endometritis, 2 (5.9%) had fibroids, and 2 (5.9%) had adenomyosis. Accuracy and P-value for TVCD and SHG were 58.82% and 0.441 and 91.17% and 0.005, respectively

Conclusion: Findings showed that there was a significant difference between color Doppler results and sono-hysterography findings. Saline infusion Sono-hysterography is significantly more accurate than transvaginal color Doppler ultrasonography in the detection of endometrial polyps.

Keywords: Color Doppler sonography; Endometrial polyp; Sono-hysterography; Hysteroscopy

INTRODUCTION:

Uterine polyps are a common cause of vaginal bleeding in pre- and postmenopausal women, mostly benign; however, it carries risk of pre-malignancy, hysteroscopic biopsy is the gold standard in diagnosis⁽¹⁾.

Uterine polyps are abnormal growth, with morphologic subtypes; sessile or

elongated pedunculated lesions of different size that project into endometrial cavity. They are the most frequently observed pathological finding in the uterus.

They may be asymptomatic or symptomatic, causing irregular menstrual bleeding, bleeding between menstrual periods, excessively heavy menstrual

bleeding (menorrhagia)⁽²⁾, and vaginal bleeding after menopause⁽³⁾. It has been a causative relation between uterine polyps and infertility⁽⁴⁾ how polyps engage in subfertility and pregnancy loss is unclear, even it can miscarriage women undergoing IVF it may interfere with sperm transport, embryo implantation, or intrauterine inflammation⁽⁵⁾.

The pathogenesis and history of endometrial polyps is unknown, however there are theories believed to be related to estrogen stimulation, the risk factors for endometrial polyp formation includes obesity, increased endogenous estrogen, high blood pressure and exogenous estrogen administration (Tamoxifen, a uterine estrogen agonist used to treat breast cancer)⁽⁶⁾.

Diagnosis of uterine polyps can be done through: Transvaginal Ultrasonography (TVUS) which consider the primary modality for assessment of endometrial abnormalities⁽⁷⁾, Colour flow Doppler which demonstrate the feeding vessel of endometrial polyp, Sono-hysterography (saline infusion hysteroqram) which is more accurate than ultrasound alone, MRI because of its good soft tissue contrast resolution in cases of vaginal or cervical stenosis, Hysteroscopy and histological diagnosis is the gold standard^(3,8,9&10).

Management of endometrial polyps is done through hysteroscopic polypectomy which is considered the most optimal treatment of endometrial polyps⁽¹¹⁾, also through Dilatation and curettage (D&C) however there is a potential for polyps to be missed due to their mobility⁽¹⁰⁾.

The purpose of our study is to evaluate the diagnostic performance and the accuracy of Color Doppler and saline infusion sono-hysterography in diagnosis of endometrial polyps and comparing them with hysteroscopy & biopsy.

AIM OF THE WORK:

The aim of this study is to compare the diagnostic performance of transvaginal color Doppler sonography (TVCD) and sono-hysterography (SHG) in the diagnosis of endometrial polyps.

PATIENTS AND METHODS

Study population: A prospective study was conducted in the Radiodiagnosis department in Ain-shams University hospital. The study was performed in 8-month period from March 2021 till October 2021, including 34 consecutive women patients aged from 28 to 55 years, with gynecological symptoms of menorrhagia, metrorrhagia and infertility. All patients included in the study were subjected to both transvaginal color Doppler sonography, saline infusion sono-hysterography in the radiodiagnosis department and then patients is scheduled for hysteroscopic biopsy in early cancer detection & Gyn Endoscopy unit, Maternity Hospital, Ain Shams University.

Inclusion criteria included women in early proliferative phase of menstrual cycle with suspected uterine polyp by transvaginal grey scale U/S and suffering from menorrhagia, dysmenorrhea, metrorrhagia or infertility.

Exclusion criteria included any patient not diagnosed with uterine polyp by transvaginal grey scale U/S, patients with genital tract infection, pregnant women, women in late menstrual phase, intrauterine device, women with cervical stenosis or patulous os and women with endometrial cancer.

Transvaginal color Doppler Ultrasound: An informed verbal consent was obtained after explaining the procedure to the patient.

Examination was performed with the patient in a lithotomy position. All scans will be performed using the US scanner (LOGIQ P5 MACHINE) in two perpendicular planes with high-frequency trans-vaginal transducers. Grey scale and colour Doppler will be performed to confirm diagnosis by visualization of pedicle vascularity.

Saline infusion sono-hysterography: Non-steroidal anti-inflammatory drug (NSAIDs) as ibuprofen (400mg) is administrated half an hour before the examination, the patient lies in lithotomy position and vaginal speculum is introduced then vagina is painted with antiseptic solution, the upper cervical lip is grasped with a vulsellum.

A silicone Foley catheter of gauge 10-16 (according to size of cervical canal) is flushed with saline to get rid of air then introduced through the internal os then bulb is inflated with 3 ml of normal saline (or Intra-uterine insemination IUI catheter used to avoid balloon painful sensation), then speculum and vulsellum is removed.

Trans-vaginal probe is introduced, and 50 ml of warm sterile saline is infused slowly to distend the endometrium cavity under real time guidance, uterine images and

findings are noted by specialized radiologist, at the end of the examination the bulb is emptied, and catheter removed, after evaluating the endometrial cavity for thickness, irregularities, or lesions (polyps).

Statistical analysis: Statistical analysis was conducted using SPSS 22nd edition, numeric variables as age was presented in mean \pm SD. Categorical data were presented in frequency and percentages, paired comparison of diagnostic modalities was conducted using McNemar test. Sensitivity, specificity, positive predictive value, negative predictive value and diagnostic accuracy were calculated using 2X2 contingency tables. Any p value <0.05 was considered significant.

RESULTS:

A total of 34 females were include in our final analysis, they had a mean age $38.6 \pm$ SD 5.7 years old range from 28 to 55 years old. Among the included patients 52.9% complained of menorrhagia, while 50% complained of metrorrhagia and 50% complained of primary or secondary infertility. Colored Doppler findings among the included patients showed positive single feeding vessel findings in 55.9% while 44.1% had negative Doppler findings.

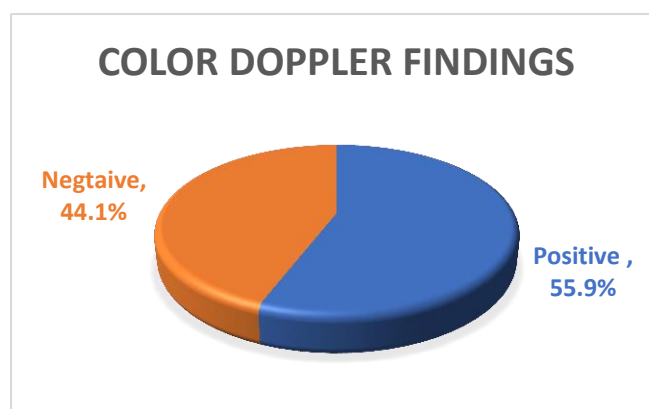


Diagram (1): Pie chart showing findings of color Doppler among the included patients

Sono-hysterography revealed positive results in diagnosis of endometrial polyps

among 88.2% of the cases while 11.8% were negative from any abnormal finding.

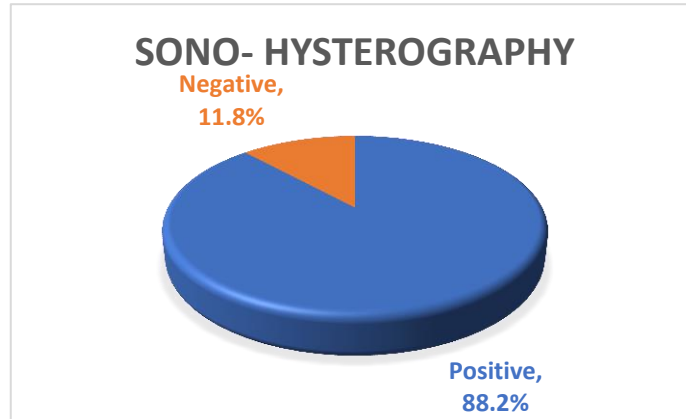


Diagram (2): Pie chart showing findings of sono-hysterography among the included patients.

Histopathology examination of the obtained specimens showed that 33 (97.1%) had endometrial polyps, while 4 (11.8%) had endometrial hyperplasia, 6 (17.6%) had endometritis, 2 (5.9%) had fibroids, 2 (5.9%) had adenomyosis.

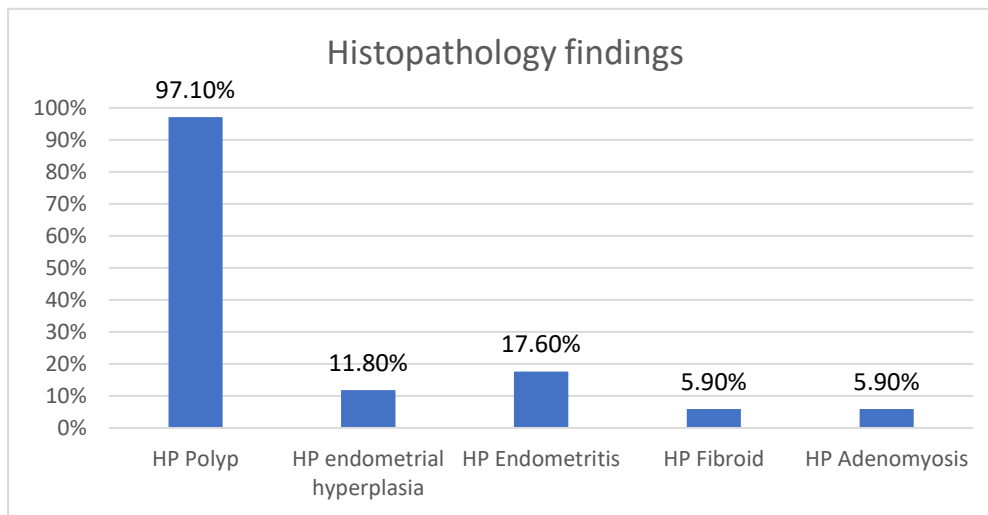


Diagram (3): Bar chart showing Histopathology findings among the included patients

Paired comparison between Histopathology findings of endometrial polyps and color Doppler findings showed that there was a statistically significant difference between histopathology results and color Doppler findings with p value 0.441.

Color Doppler had a sensitivity 57.6% in detection of endometrial polyps, specificity 100.0%, PPV 100.0%, NPV 6.7% and overall diagnostic accuracy 58.82%.

Paired comparison between Histopathology findings of endometrial polyps and sonohysterography findings

showed that there was concordance between histopathology results and sonohysterography findings with p value 0.005.

Sonohysterography had a sensitivity 90.9% in detection of endometrial polyps, specificity 100%, PPV 100%, NPV 25% and overall diagnostic accuracy 91.17%.

The figure showed high concordance between histopathology findings and sonohysterography, as positive results was 88.2% in sono-hysterography versus 55.9% in the color Doppler versus 97.1% in histopathology examinations.

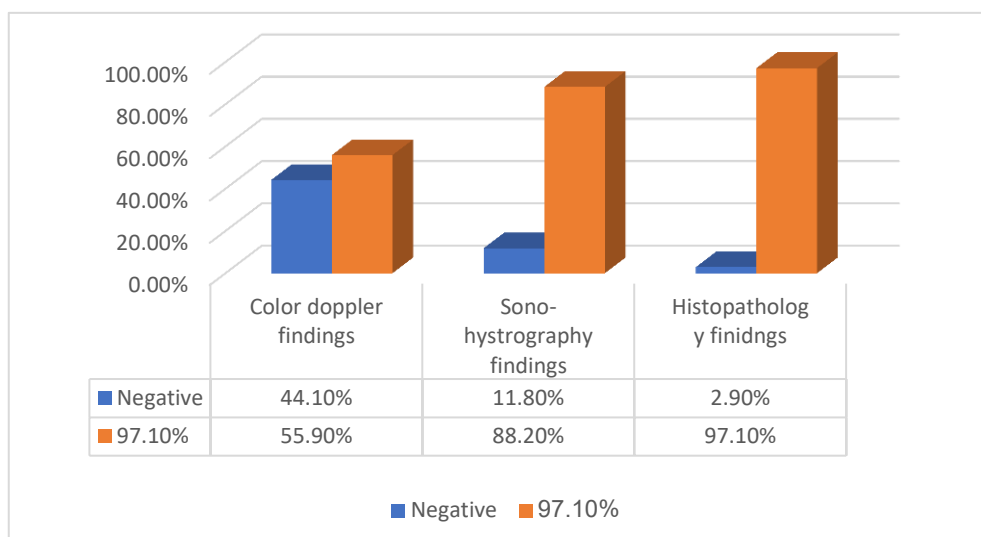


Diagram (4): Bar chart showing findings of imaging modalities and histopathology findings

DISCUSSION:

Histological examination is still the gold standard for uterine cavity pathologies such as endometrial polyps. The evaluation of abnormal uterine bleeding is traditionally based on histological diagnosis, established either with dilatation and curettage or endometrial biopsy. However, these diagnostic procedures are invasive, and they may not detect all of the endometrial abnormalities if performed alone⁽²⁾.

Transvaginal sonographic measurement of endometrial thickness has been shown to be useful method for detecting endometrial disease. However, increment endometrial thickness is not a unique finding and may be caused by other conditions, such as endometrial polyps, hyperplasia, and cancer.

Transvaginal color Doppler sonography allows assessment of endometrial vascularization. recent studies have shown that endometrial polyps demonstrate specific vascular patterns on colour flow mapping⁽¹²⁾.

This study was conducted on total of 34 females were include in our final analysis, they had a mean age $38.6 \pm SD 5.7$ years old range from 28 to 55 years old.

There were 18 patients (52.9%) presented with menorrhagia as one of the

symptoms, 17 patients (50%) presented with metrorrhagia as one of the symptoms and 17 patients (50.0%) presented with infertility as one of the symptoms.

According to our study, menorrhagia should be considered the most common symptom among clinical presentation of endometrial polyp's patients with incidence of 52.9% which comes against a study by **Alcázar et al.**⁽¹²⁾ who stated that 47% of the patients were asymptomatic. While **Amreen et al.**⁽⁷⁾ study results stated that the most common symptom was menorrhagia, (91.3%), followed by metrorrhagia (10.3%), polymenorrhea (8.6%).

SHG is a relatively inexpensive procedure that can be easily performed with no need for special skill. It provides a dependable diagnosis in the invention of endometrial polyps over TVS. However, hysteroscopy and endoscopic biopsies still the definitive diagnostic tests.

SHG was described to be a simple, secure, accurate and cost-effective method for detecting endometrial lesions⁽⁸⁾.

Sono-hysterography in our study revealed positive results for endometrial polyps in 88.2% of the cases with accuracy 91.17% which comes in line with a study by

Alcázar et al.⁽¹²⁾ which reported SHG accuracy 96% while a study by **kamel et al.**⁽⁸⁾ reported diagnostic accuracy for SHG 93.3%.

Our study in Sono-hysterography had a sensitivity 90.9% in detection of endometrial polyps, specificity 100%, PPV 100%, NPV 25% in line with **Romano et al.**⁽¹³⁾ in which their study reported a sensitivity, specificity, positive and negative predictive value of 95%, 100%, 100% and 94% respectively, for SHG in detecting endometrial lesions including polyps.

In study for **Kaveh et al.**⁽²⁾ found that saline infusion sono-hysterography (SISH) has a sensitivity of 87.9% and a specificity of 92.2% in the detection of endometrial polyps, results were consistent with the previous systematic review conducted in **Vroom et al.**⁽¹⁴⁾ which reported a sensitivity of 86.5% and specificity of 91.1% for SISH in diagnosis of endometrial polyps.

In our study trans-vaginal color Doppler (TVCD) revealed positive findings for single feeding vessel in 19 cases out of 34 with 55.9% with sensitivity 57.6% in detection of endometrial polyps, specificity 100.0%, PPV 100.0%, NPV 6.7% and overall diagnostic accuracy 58.82%.

A study by **Talaat et al.**⁽¹⁵⁾ by concluded that the pedicle artery sign has 94% sensitivity 100% specificity.

Cogendez et al.⁽¹⁶⁾ have reported the sensitivity, specificity, and positive and negative predictive values of the single vessel pattern in detecting uterine polyps were 80, 100, 100, and 69.2%, respectively.

However, provided that the only way to rule out the risk of malignancy is through hysteroscopy and biopsy, SISH can be used as a method to stratify patients with abnormal uterine bleeding (AUB) to go for more diagnostic work up and treatment with hysteroscopy. Nevertheless, hysteroscopy is an exceptionally sensitive method, allowing the relegation of intracavitary pathology

beside treatment in the same sitting with convenient biopsy from the abnormal area, which can be of help in treatment planning.

Hysteroscopy was superior to both trans-vaginal color Doppler and sono-hysterography regarding discriminating between polyps and other endometrial lesions. We calculated 97.1% positive results among the cases for hysteroscopy for diagnosis of endometrial polyps nearly like **Kaveh et al.**⁽²⁾ study which calculated a 0.92 (95% CI: 0.89–0.94) sensitivity and a specificity of 0.85 (95% CI: 0.81–0.88) for hysteroscopy.

This study used histological diagnosis as the gold standard and assessed the accuracy of transvaginal color Doppler and saline infusion sono-hysterography in predicting endometrial polyps.

Histopathology examination of the obtained hysteroscopic specimens showed that 33 (97.1%) of cases had endometrial polyps, while 4 (11.8%) had endometrial hyperplasia, 6 (17.6%) had endometritis, 2 (5.9%) had fibroids and 2 (5.9%) had adenomyosis.

Our study showed that there was concordance between histopathology results and sonohysterography findings with p value 0.005.

A study performed by **Cepni et al.**⁽¹⁷⁾ showed a sensitivity of 94% and a specificity of 58% for hysteroscopic diagnosis of endometrial polyps.

Our study showed high concordance between histopathology findings and sono-hysterography, as positive results was 88.2% in sono-hysterography versus 55.9% in the color Doppler versus 97.1% in histopathology examinations.

Conclusion:

As per our results, color Doppler findings of endometrial polyps and sono-hysterography findings showed that there was a significant difference between color

Doppler results and sono-hysterography findings while there was high concordance between histopathology results and sono-hysterography findings.

This proves the superiority of sono-hysterography over color Doppler sonography in diagnosis of uterine polyps.

Sono-hysterography results closely correspond to those obtained in a hysteroscopic examination combined with histopathological analysis.

Competing interests: Not applicable, the authors have no conflicts of interest to declare.

Funding: No financial support was received for this study/work.

REFERENCES

1. Çil AS, Bozkurt M, Kara D, Guler B. Giant endometrial polyp protruding from the external cervical os in a postmenopausal woman: magnetic resonance imaging and hysteroscopic findings. *Proceedings in Obstetrics and Gynecology*. 2013; 3(3):1-9.
2. Kaveh M, Sadegi K, Salarzaei M & Parooei F. Comparison of diagnostic accuracy of saline infusion sonohysterography, transvaginal sonography, and hysteroscopy in evaluating the endometrial polyps in women with abnormal uterine bleeding: A systematic review and meta-analysis. *Wideochirurgia I Inne Tech. Maloinwazyjne*, 2020; 15, 403–415.
3. Hase S, Mitsumori A, Inai R. Endometrial polyps: MR imaging features. *Acta Med Okayama*. 2012; 66(6):475-485.
4. Hinckley MD and Milki AA. 1000 Office-Based Hysteroscopies Prior To In vitro Fertilization: Feasibility and Findings. *JSLs*, 2004; 8, 103–107.
5. Al Chami A & Saridogan E. Endometrial Polyps and Subfertility. *J. Obstet. Gynecol. India* 67, 2017; 9–14.
6. Nijkang NP, Anderson L, Markham R & Manconi F. Endometrial polyps: Pathogenesis, sequelae and treatment. *SAGE Open Med*, 7: 2019; 205031211984824.
7. Amreen S, Singh M, Choh NA, Saldanha C & Gojwari TA. Doppler evaluation of endometrial polyps. *Egypt. J. Radiol. Nucl. Med* 49, 2018; 850–853.
8. Kamel HS, Darwish AM, Mohamed SA. Comparison of transvaginal ultrasonography and vaginal sonohysterography in the detection of endometrial polyps. *Acta obstetrica et gynecologica Scandinavica* 2000; 79(1):60-4.
9. Ahmed SA, El Taieb HA, Abotaleb H., Diagnostic performance of sonohysterography and MRI diffusion in benign endometrial lesion characterization. *The Egyptian journal of radiology and nuclear medicine*, 2018; 49(2):579-89,
10. Nijkang NP, Anderson L, Markham R & Manconi F. Endometrial polyps: Pathogenesis, sequelae and treatment. *SAGE Open Med*.7, 2019; 205031211984824.
11. Lieng M, Istre O & Qvigstad E. Treatment of endometrial polyps: A systematic review. *Acta Obstet. Gynecol. Scand*, 2010; 89, 992–1002.
12. Alcázar JL, Castillo G, Mínguez JA, Galán MJ. Endometrial blood flow mapping using transvaginal power Doppler sonography in women with post- menopausal bleeding and thickened endometrium. *Ultrasound Obstet Gynecol* 2003; 21:583–588
13. Romano F, Cicinelli E, Anastasio P, Epifani S, Galantio P. Sonohysterography versus hysteroscopy for diagnosing endouterine abnormalities in fertile women. *Int J Gynaecol Obstet* 1994; 45: 253–60
14. Vroom AJ, Timmermans A, Bongers MY. Diagnostic accuracy of saline contrast sonohysterography in detecting endometrial polyps in women with postmenopausal bleeding: systematic review and meta-analysis. *Ultrasound Obstet Gynecol* 2019; 54: 28-34.
15. Talaat S, Mostafa N, Alraouf MABD. Diagnostic value of ultrasound and colour Doppler in endometrial and cervical polyps. *Med. J.Cairo Univ*. 2009;77:397–403

16. Cogendez E, Eken MK, Bakal N. The role of transvaginal power Doppler ultrasound in the differential diagnosis of benign intrauterine focal lesions. J Med Ultrason 2015; 42:533–40.
17. Cepni I, Ocal P, Erkan S, Saricali FS, Akbas H, Demirkiran F. Comparison of transvaginal sonography, saline infusion sonography and hysteroscopy in the evaluation of uterine cavity pathologies. Aust N Z J Obstet Gynaecol 2005;45(1):30-5.

دور الموجات الصوتية و الدوبلر المهبلي باستخدام محلول الملح في تقييم مرض الزوائد اللحمية في الرحم

ساره محي الدين عبد المنعم*، سامر ملاك بطرس**، أسماء مجدى محمد**

قسم الاشعة التشخيصية، مستشفى المقطم تأمين صحى، القاهرة، مصر*

قسم الاشعة التشخيصية، كلية الطب، جامعه عين شمس، القاهرة، مصر**

المقدمة: الزوائد اللحمية في الرحم هي النمو الغير طبيعى لبطانة الرحم و ظهورها كزوائد ذات احجام مختلفه فى تجويف الرحم. وهى تعد من اكثر الاكتشافات المرضيه التى تم ملاحظاتها فى الرحم. قد ياتى بعض المرضى بدون اعراض والبعض الاخر قد يعانون من نزيفا غزيرا فى الدورة الشهرية (غزاره الطمث)، او نزيفا مهبلياً بعد انقطاع الطمث.

الهدف من الدراسه: هو تقييم الاداء التشخيصى لمرض الزوائد اللحمية فى الرحم باستخدام الدوبلر المهبلي بالاضافة إلى التصوير بالموجات الصوتية مع تدفق محلول الملح ومقارنة دقتهم فى التشخيص سويًا مع استخدام المنظار الرحمى واخذ عينه من الزائده اللحمية.

الطرق: تم اجراء دراسته على نحو ٣٤ مريضه تتراوح اعمارهم من ٢٨ الى ٥٥ عاما تم تحويلهم من قسم النساء و العيادات الخارجيه الى قسم الاشعة التشخيصيه بمستشفى عين شمس لاجراء فحص الموجات الصوتيه و الدوبلر المهبلي باستخدام محلول الملح ثم تم توجيههم لوحده الكشف المبكر عن الاورام لعمل منظار و عينه رحميه.

النتائج: اظهرت الدراسه ان نسبة تشخيص الزوائد اللحمية الرحميه بالدوبلر المهبلي هي ٥٥.٩% من نسبة الحالات، بينما اظهر التشخيص بالموجات الصوتيه المهبليه عن طريق تدفق محلول الملح نسبة ٨٨.٢%، فى حين ان نتائج عينات المنظار الرحمى ظهرت بنسبه ٩٧.١%.

مما يدل عن وجود تشابه و تقارب بين النسبه التشخيصيه للموجات الصوتيه المهبليه عن طريق تدفق محلول الملح و النسبه التشخيصيه للمنظار الرحمى.

الخلاصه: تشير الدراسه ان النتائج التى تم الحصول عليها من خلال فحص الموجات الصوتيه المهبليه باستخدام محلول الملح يمكن الاعتماد عليها فى تقييم مرض الزوائد اللحمية الرحميه.

كما يمكن استخدام هذا الفحص لمتابعه المرضى و تقييم تطور المرض و درجا استجابهم للعلاج.