

## SHORT AND LONG TERM EFFECTS OF THE TUMOUR NECROSIS FACTOR INHIBITOR ON THE REGENERATION PROCESS OF SCIATIC NERVE TRANSECTION IN ALBINO RAT

Ashraf M. Sadek <sup>(1)</sup>, Nawal F. Rizkallah <sup>(1)</sup>, Hossam M. Elhosseiny <sup>(2)</sup>, Hoda M. Mahmoud <sup>(1)</sup>, George F.B. Hanna <sup>(1)</sup> and Mohamed M. Sonbol <sup>(1)</sup>.

### ABSTRACT:

<sup>1</sup> Human anatomy & Embryology and <sup>2</sup>Neurosurgery Departments, Faculty of Medicine, Ain-Shams University

#### Corresponding author

Mohamed M. Sonbol,  
Mobile: +20 01224406865  
E.mail:

[drmohamed\\_sonbol@med.asu.edu.eg](mailto:drmohamed_sonbol@med.asu.edu.eg)

Received: 21/11/2022

Accepted: 30/11/2022

Online ISSN: 2735-3540

**Background:** In peripheral nerve damage, pro-inflammatory cytokines, such as tumour necrosis factor-alpha (TNF- $\alpha$ ) are rapidly recruited mediating many of the deleterious events associated with Wallerian degeneration.

**Aim of the work:** Identify the short and long-term effects of TNF- $\alpha$  inhibitor on the nerve regeneration after experimental sciatic nerve transection.

**Material and methods:** 36 adult male albino rats were divided into 3 groups, 12 rats each. Group A (control) was subdivided into 2 subgroups (A1 & A2). A1 left without any intervention and A2 (sham), half of each subgroup were sacrificed after 1 and 8 weeks. Group B (untreated) was subdivided into 2 subgroups (B1 & B2), sciatic nerve transection was done, B1 was sacrificed after 1 week and B2 after 8 weeks. Group C (treated) was subdivided into two subgroups (C1 & C2), sciatic nerve transection and immediate intraperitoneal injection with anti-TNF- $\alpha$  (Enbrel 25 mg) vial 6 mg/kg single dose was done. C1 was sacrificed after 1 week and C2 after 8 weeks. Nerve endings for all groups were processed for light, transmission electron microscope, immunohistochemical (ED1 cell and S100 antigen), morphometric and statistical studies.

**Results:** 1 week after injury macrophage cells (MC) invasion and excessive demyelination occurred, anti-TNF- $\alpha$  reduced the MC invasion. 8 weeks after the injury regenerating myelinated axons were observed. Number of the regenerating axons showed statistically significant increase in the treated group compared to the injured group.

**Conclusion:** Immediate administration of TNF- $\alpha$  antagonist after induced sciatic nerve injury enhanced nerve regeneration.

**Keywords:** Tumour necrosis factor inhibitor, Sciatic nerve transection, Albino rats.

### INTRODUCTION:

The axons of the peripheral nerves can regenerate and regrow after damage by a process termed Wallerian degeneration. This process is associated with macrophage infiltration and Schwann cell proliferation<sup>(1)</sup>.

After injury pro-inflammatory cytokines, e.g., tumour necrosis factor-alpha (TNF- $\alpha$ ) and its receptor tumour necrosis factor receptor 1 (TNFR1) are up-regulated rapidly at the site of the peripheral nerve injury<sup>(2)</sup>. After tumour necrosis factor- $\alpha$  signalling, metabolic reprogramming of macrophages occurred with polarization of

macrophages from a reparative state to a pathogenic and inflammatory state<sup>(3)</sup>.

Since the nervous system is characterized by the dependence of the neurons on their supporting glia; regeneration in the peripheral nervous system is possible<sup>(4)</sup>. Injury to peripheral neurons results in a sequence of molecular and cellular responses that may play an important role in successful axonal regeneration and recovery of function<sup>(5)</sup>.

Etanercept is a biopharmaceutical product that treats autoimmune diseases by acting as tumour necrosis factor inhibitor<sup>(6)</sup>. It is a large molecule, with a molecular weight of 150 kDa, that binds to TNF $\alpha$  and decreases its role in disorders involving excess inflammation in humans<sup>(7)</sup>.

Sciatic nerve injuries are considered as a complex type of peripheral nerve injury that cause partial or total loss of motor, sensory and autonomic functions due to the axon discontinuity and degeneration which result in functional loss and decreased quality of life<sup>(8)</sup>.

So, it became the aim of the present work to identify the short and long-term effects of alpha tumour necrosis factor inhibitor on the peripheral nerve regeneration following experimental sciatic nerve transection.

---

### **AIM OF THE WORK:**

Identify the short and long-term effects of TNF-  $\alpha$  inhibitor on the nerve regeneration after experimental sciatic nerve transection.

---

### **MATERIAL AND METHODS:**

#### **Animals:**

This study was carried out on 36 healthy adult male albino rats with good fur aged 3-6 months and weighing 180-200 gm. Animals were obtained and locally bred at the animal

facility of Faculty of Medicine Ain Shams Research Institute (MASRI).

Rats were housed in medium sized metal cages in room temperature, with adequate ventilation, regular dark/light cycles and were given free diet and water access. All rats were kept under the same circumstances throughout the experiment and were given two-weeks acclimatization period prior to the experiment.

The experimental protocol was approved by the Committee of Animal Research Ethics (CARE), Faculty of Medicine - Ain Shams University.

#### **Experimental sciatic nerve transection:**

Sciatic nerve transection was unilaterally induced in rats at the mid-thigh level under anaesthesia. All surgical procedures were performed under aseptic conditions using microsurgical techniques. The animals were anesthetized with 4% Isoflurane (IsoSol; Vedco, St. Joseph, MO). About 10 mm of sciatic nerve was exposed unilaterally at the mid-thigh level through a gluteal muscle-splitting incision. Nerve injury was performed by transection of the nerve and subsequent reconnection by end to-end neurorrhaphy.

Reconnection of nerve stumps was done by epineurial or perineurial sutures without tension. The crush site was labelled using a 6-0 nylon suture to the adjacent muscle. The sham operation included unilateral sciatic nerve exposure. The muscle layer was closed with silk sutures, and the skin was closed with silk suture.

#### **Chemical used and dosage:**

Etanercept was used in the form of Enbrel 25 mg vial. Treated groups were injected 6.0 mg/kg B. W as a single dose immediately intraperitoneally after sciatic nerve transection<sup>(9)</sup>.

### **Experimental protocol:**

36 adult male albino rats were divided into 3 groups, 12 rats each.

#### **Group A (control):**

Included 12 rats, they were equally divided into two subgroups:

- Subgroup A1 left without intervention.
- Subgroup A2 (sham).

Half of each subgroup were sacrificed after 1 week and the other half after 8 weeks.

#### **Group B (untreated nerve injury):**

Included 12 rats that were subjected to transection of the sciatic nerve and intraperitoneal saline injection, then subdivided into 2 subgroups:

- Subgroup B1: rats were sacrificed after 1 week.
- Subgroup B2: rats were sacrificed after 8 weeks.

#### **Group C (treated nerve injury):**

Included 12 rats that were subjected to transection of the sciatic nerve and received intra-peritoneal injection of 6 mg/kg B. W. tumour necrosis factor alpha inhibitor, then subdivided into 2 subgroups:

- Subgroup C1: rats were sacrificed after 1 week.
- Subgroup C2: rats were sacrificed after 8 weeks.

At the end of the experiment for each subgroup, rats were anesthetized using intra-peritoneal pentobarbital prior to sacrifice, the sciatic nerves 5mm distal to the lesion were excised for analyses.

### **Histological study:**

#### **Light microscopic examination:**

Nerve samples were fixed in 10% formalin for 48h, dehydrated, cleared, and embedded in paraffin to create paraffin

blocks. Then 5  $\mu$ m sections were cut and stained with haematoxylin & eosin <sup>(10)</sup>.

Olympus light microscope (CX31) in the Anatomy Department, Faculty of Medicine, Ain Shams University was used to examine and photograph the stained sections.

#### **Semithin and ultrathin sections:**

Nerve samples measuring 1 mm<sup>3</sup> were fixed in 2.5% glutaraldehyde for 24 hours, washed twice in phosphate buffer, fixed in 1% osmic acid for one hour at room temperature, twice washing of the slides again in phosphate buffer for half an hour each was done, dehydrated in ascending grades of ethyl alcohol, cleared in propylene oxide for 20 minutes, and embedded in Epon resin. Semithin sections 1  $\mu$ m in thickness were obtained with glass knives on ultramicrotome, stained with 1% toluidine blue with pH 7.3 and examined by an Olympus light microscope to choose the selected areas.

Ultrathin sections 50 nm were cut using a glass knife, mounted on copper grids, stained with uranyl acetate for 20 minutes and lead citrate for 10 minutes, and then they were washed in distilled water & preserved in labelled capsules <sup>(11)</sup>. Transmission electron microscope in the Faculty of Science, Ain Shams University, Egypt, was used to view and photograph the obtained sections.

#### **Immunohistochemical examination:**

Immunohistochemical staining was carried out using the avidin-biotin technique <sup>(10)</sup>. Immunohistochemical staining was done 4  $\mu$ m thick paraffin sections, the sections were fixed on charged microscopic slides followed by deparaffinization with Xylene then hydrated through descending grades of ethanol, the slides then were rinsed in distilled water. Heat induced antigen retrieval using preheated sodium citrate solution in a microwave oven for 15 minutes was done.

The slides were incubated in 1% hydrogen peroxide solution (DAKO) for 20 minutes for blocking the endogenous peroxidase activity, hydrogen peroxide was washed off the slides through three washes of phosphate buffer saline.

Blocking of nonspecific binding sites: incubating the slides overnight at +4 °C in PBS (phosphate buffer saline) +5% bovine serum albumin +1 % sodium azide. Blocking of the biotin sites done with the avidin/ biotin blocking kit.

Antibody incubations were done as mentioned later then the slides were rinsed in running tap water for 2-5 minutes, dehydrated through 95% ethanol for 1 minute, 100% ethanol for 6 minutes, cleared in xylene for 10 minutes and cover slipped with DPX mounting medium.

#### **Incubation with antibodies:**

Incubation with antibodies against ED 1 cell (Chemicon, 1:50 dilution) and S-100 antigen (1:300 dilution, polyclonal rabbit anti-cow-DAKO Z0311) for the detection of inflammatory cells and Schwann cells respectively, the reaction appeared as brownish cytoplasmic granules. The slides were lightly counterstained with Mayer's haematoxylin to assist in tissue visualization.

#### **Morphometric study:**

The measurements were done using image analyser in Anatomy Department -Ain Shams University as follow:

1) Axons count was done by using point selection per microscopic field unit at the objective lens of 100x in semithin sections, measurements were taken from six microscopic fields per slide, six slides per rat and 6 rats per group.

2) Quantitation of immunoreactivity S100 antigen were done after image splitting. Images were splitted into RGB stacks then red stack was adjusted to threshold to mark it with a binary mask. Then the area percent in relation to the field was calculated at the objective lens of 40x.

#### **Statistical analysis:**

The data were recorded, entered, and processed on a compatible computer using SPSS program (version 13.0) for windows (Statistical Package for the Social Sciences).

One-way analysis of variance (ANOVA) was employed to compare means between groups<sup>(12)</sup>. The significance of the data was determined by the probability (P-value).  $P > 0.05$  was considered insignificant,  $P < 0.05$  was considered significant, and  $P < 0.001$  was considered highly significant. Data were represented in tables.

---

## **RESULTS:**

### **Histological results:**

#### **Examination of the control group:**

Light microscopic examination of haematoxylin and eosin-stained sections of rat sciatic nerve in both control subgroups showed similar histological appearance. The sciatic nerve axons appeared as longitudinal bundles with peripherally situated Schwann cells (**Fig.1**). Semithin sections stained with toluidine blue showed the myelinated and unmyelinated nerve fibres as well as the blood vessels (**Fig.2**).

Electron microscopic examination of the ultrathin sections showed myelinated fibers with their axoplasm containing mitochondria. The myelinated nerve fibers were surrounded by Schwann cells. The Schwann cell wraps around the nerve fibre to form a multi-laminated myelin sheath (**Fig.3**).

Immunohistochemically stained sections showed no immunoreactivity against ED1 cells (**Fig.4**) and showed strong immunoreactivity to S100 antigen (**Fig 5**).

#### **Sciatic nerve sections one week after the transection (groups B1 and C1):**

Light microscopic examination of haematoxylin and eosin-stained sections in the untreated **B1** subgroup revealed morbid invasion of macrophage cells (**Fig.6**).

Semithin sections stained with toluidine blue showed appreciable invasion of macrophage cells phagocytosing myelin sheath and contained myelin debris (Fig.7). Electron microscopic examination of the ultrathin sections showed multiple macrophages containing myelin debris (Fig.8). Immunohistochemically stained sections showed avid immunoreactivity against ED1 cells (Fig.9), and minimal immunoreactivity to S-100 antigen (Fig.10).

Light microscopic examination of haematoxylin and eosin-stained sections of the treated subgroup C1 revealed apparent reduction in the macrophage cells invasion and the presence of mononuclear inflammatory cells (Fig.11). Semithin sections stained with toluidine blue showed minimal invasion of macrophage cells (Fig. 12).

Electron microscopic examination of the ultrathin sections showed macrophage cells phagocytose myelin sheath forming myelin debris with multiple vacuoles (Fig. 13). However, their number was apparently fewer than that in subgroup B1. Also notice appearance of remyelination of the axons (Fig13).

As a result, to the reduced number of macrophage cells invasion and minimal demyelination,

immunohistochemically stained sections showed weak immunoreactivity against ED1 cells (Fig.14) and showed moderate immunoreactivity to S-100 antigen (Fig.15).

### Sciatic nerve sections 8 weeks after the transection (subgroups B2 and C2):

Light microscopic examination of haematoxylin and eosin-stained sections in subgroup B2 showed axon regeneration with no inflammatory cells (Fig. 16). Semithin sections stained with toluidine blue showed regenerating axons and their myelination (Fig. 17). Electron microscopic examination of the ultrathin sections showed the definitive myelinated and unmyelinated nerve fibers (Fig. 18). However, there was still weak immunoreactivity to ED1 cells (Fig. 19) and moderate immunoreactivity to S-100 antigen (Fig. 20).

Light microscopic examination of haematoxylin and eosin-stained sections in subgroup C2 revealed regeneration of the axons with the absence of the inflammatory cells (Fig. 21). Semithin sections stained with toluidine blue showed the appearance of the regenerating axons and its myelination. However, the number of the myelinated fibers was apparently increased as compared to B2 subgroup (Fig.22).

Electron microscopic examination of the ultrathin sections revealed regenerating axons with myelin sheath and unmyelinated fibers, the myelinated fibers showed Schmidt-lanterman clefts (Fig. 23).

Immunohistochemically stained sections showed no immunoreactivity to ED 1 cells (Fig. 24) and showed a strong immunoreactivity to S-100 antigen in comparison with B2 subgroup (Fig. 25).

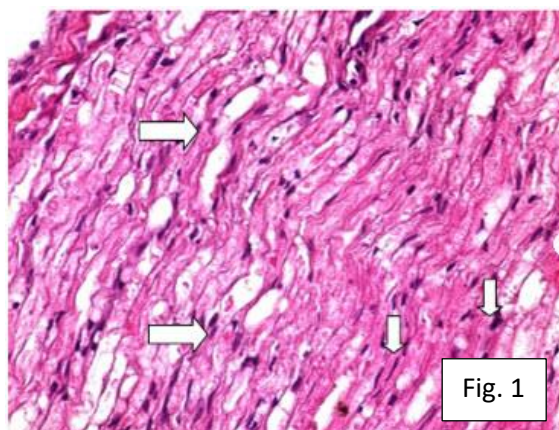


Fig. (1): A photomicrograph of longitudinal section of sciatic nerve of the control group, showing the nerve axons and nuclei of Schwann cells Hx. & E., X400

**Fig. (2):** A photomicrograph of transverse section of sciatic nerve of the control group. Notice the myelinated fibers  $\Rightarrow$  and the unmyelinated fibers  $\Delta$ .  
**Toluidine blue, X1000**

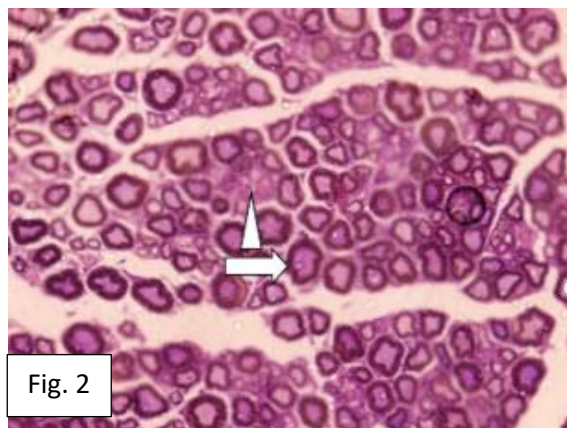


Fig. 2

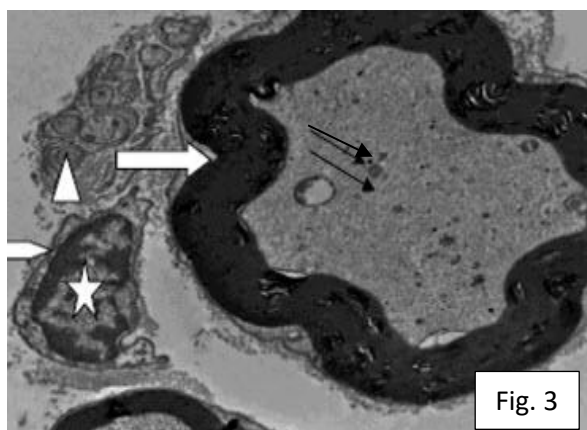


Fig. 3

**Fig. (3):** An electron-micrograph of an ultrathin section of sciatic nerve of the control group, showing myelinated fibers  $\Rightarrow$  with their axoplasm containing mitochondria  $\rightarrow$ . The myelinated nerve fibers are surrounded by Schwann cell  $\square$  Notice the Schwann cell nucleus  $\star$ . The unmyelinated axons which are circular or ovoid in shape are grouped in a cluster  $\wedge$ .  
**Uranyl acetate & Lead citrate, X10000**

**Fig. (4):** A photomicrograph of transverse section of the sciatic nerve of the control group, showing no immunoreactivity against ED1 cell antigen.  
**Avidin-biotin technique, x400**

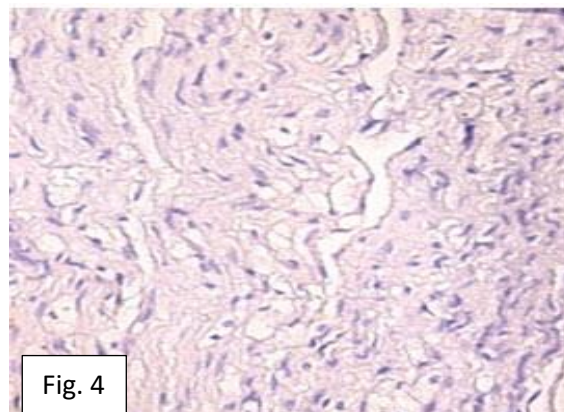


Fig. 4

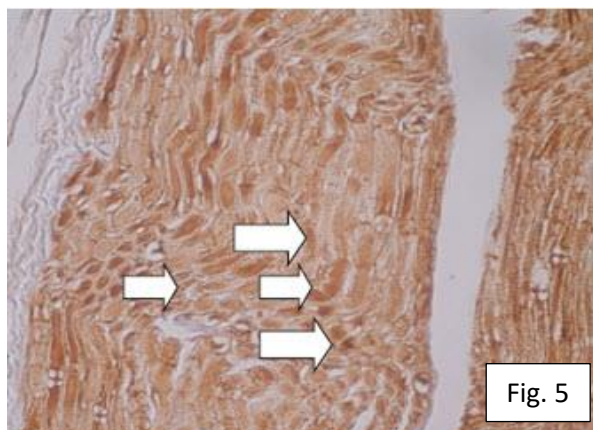
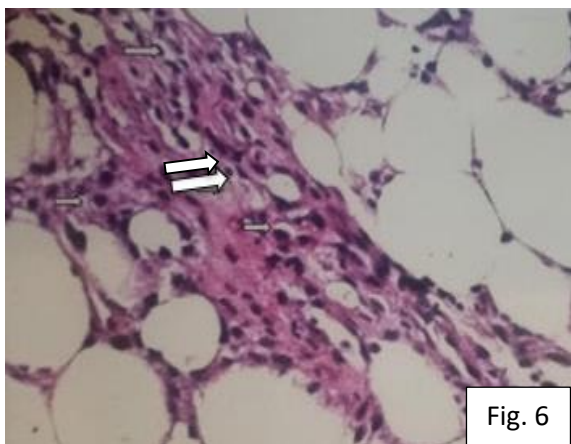


Fig. 5

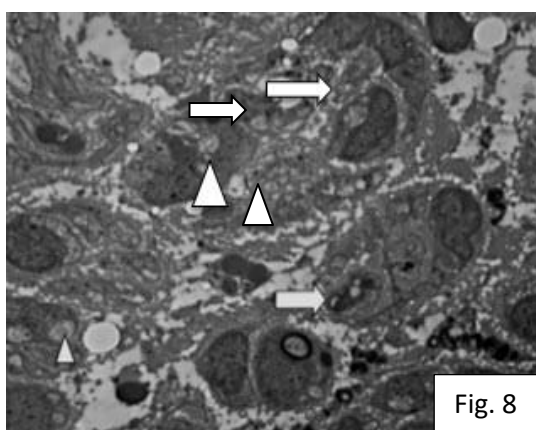
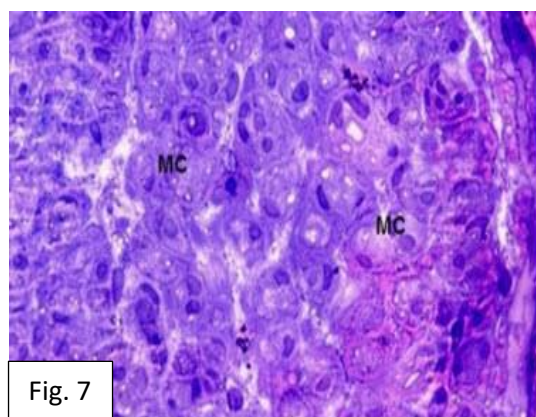
**Fig. (5):** A photomicrograph of a longitudinal section of the sciatic nerve of the control group, showing strong S-100 immunoreactivity reaction  $\Rightarrow$  in Schwann cells.

**Avidin-biotin technique, x400**



**Fig. (6):** A photomicrograph of transverse section of sciatic nerve of the injured subgroup B1, 1 week after injury, showing excessive invasion of macrophage cells  $\Rightarrow$  **Hx. & E., X400**

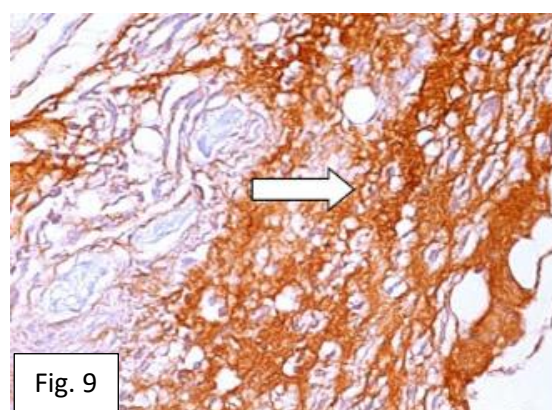
**Fig. (7):** A photomicrograph of transverse section of sciatic nerve of the injured subgroup B1, 1 week after injury, showing invasion of macrophage cells containing myelin debris (MC). **Toluidine blue, X1000**

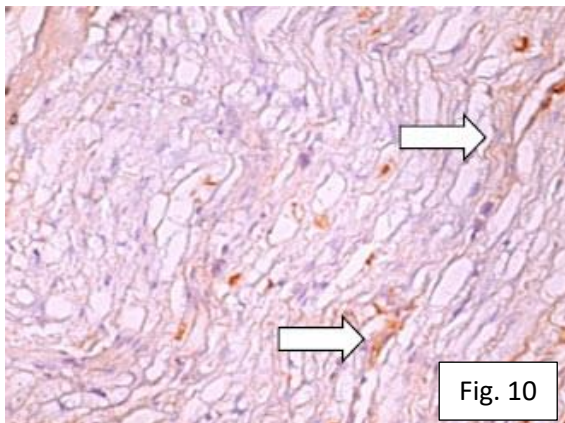


**Fig. (8):** An electron-micrograph of an ultrathin section of sciatic nerve of the injured subgroup B1, 1 week after injury, showing multiple macrophages containing myelin debris  $\Rightarrow$  . Also notice the multiple vacuoles  $\Delta$  .

**Uranyl acetate & Lead citrate, X2000**

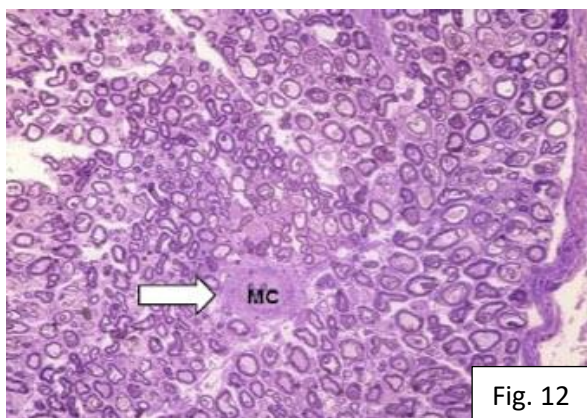
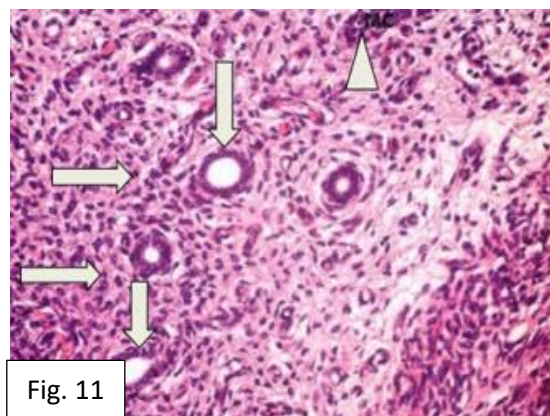
**Fig. (9):** A photomicrograph of transverse section of sciatic nerve of the injured subgroup B1, 1 week after injury. Notice strong immunoreactivity against ED 1 cell  $\Rightarrow$  . **Avidin-biotin technique, x400**





**Fig. (10):** A photomicrograph of longitudinal section of sciatic nerve of the injured subgroup B1, 1 week after injury, showing minimal immunoreactivity to S- 100 antigen.  
**Avidin-biotin technique, x400**

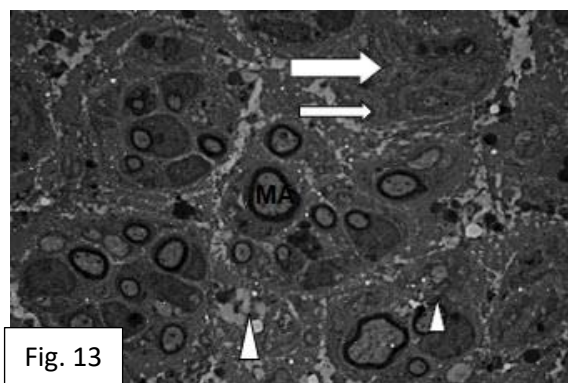
**Fig. (11):** A photomicrograph of transverse section of sciatic nerve of the treated subgroup C1, 1 week after injury showing presence of inflammatory cells  $\rightarrow$  around the blood vessels  $\downarrow$  also noticed the presence of the macrophage cells (MC)  $\Delta$ . **Hx. & E., X400**



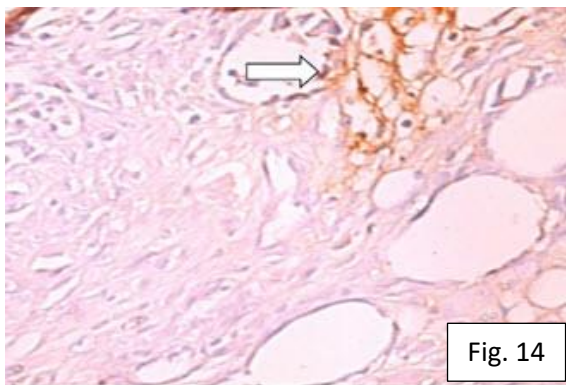
**Fig. (12):** A photomicrograph of transverse section of sciatic nerve of the treated subgroup C1, 1 week after injury, showing macrophage cell (MC)  $\rightarrow$ , notice the beginning of remyelination of the axons. **Toluidine blue, X400**

**Fig. (13):** An electron-micrograph of an ultrathin section of sciatic nerve of the treated subgroup C1, 1 week after injury, showing macrophage cells containing myelin debris  $\rightarrow$ , and vacuoles  $\Delta$ . Notice the beginning of remyelination of the axons (MA)

**Uranyl acetate & Lead citrate, X2000**

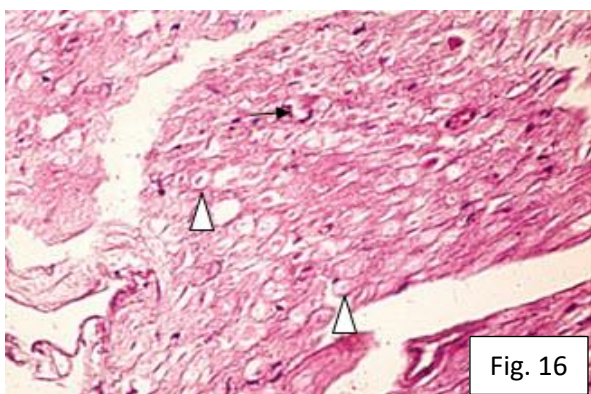
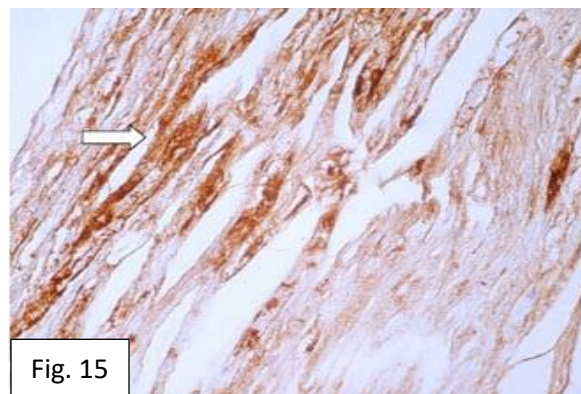






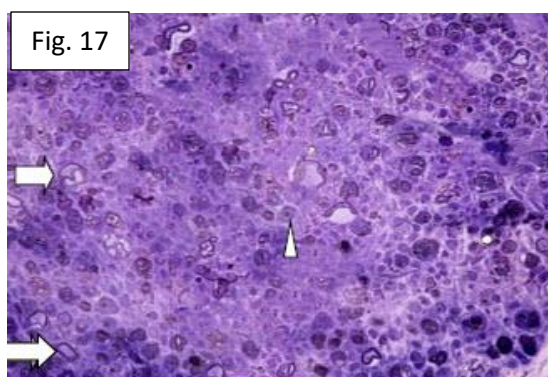
**Fig. (14):** A photomicrograph of transverse section of sciatic nerve of the treated subgroup C1, 1 week after injury, showing weak immunoreactivity against ED 1 cell  $\rightarrow$ .  
**Avidin-biotin technique, x400**

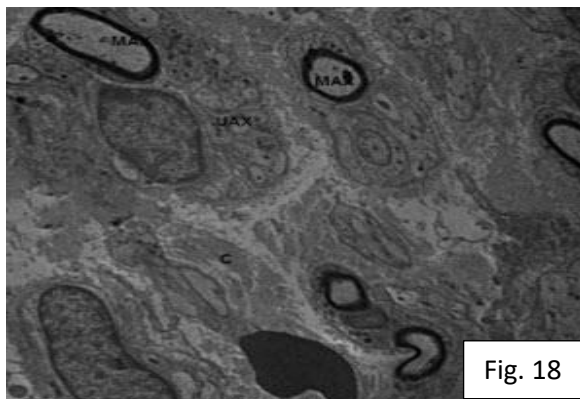
**Fig. (15):** A photomicrograph of longitudinal section of sciatic nerve of the treated subgroup C1, 1 week after injury, showing moderate immunoreactivity to S- 100 antigen  $\rightarrow$ .  
**Avidin-biotin technique, x400**



**Fig. (16):** A photomicrograph of transverse section of sciatic nerve of the injured subgroup B2, 8 weeks after injury showing the regenerating axons  $\Delta$  with some inflammatory cells.  $\rightarrow$   
**Hx. & E., X400**

**Fig. (17):** A photomicrograph of transverse section of sciatic nerve of the injured subgroup B2, 8 weeks after injury showing the appearance of regenerating myelinated nerve fibers  $\rightarrow$  and unmyelinated fibers  $\Delta$  .  
**Toluidine blue, X400**

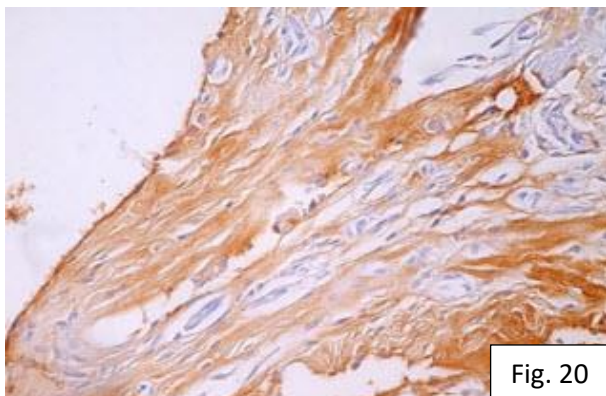
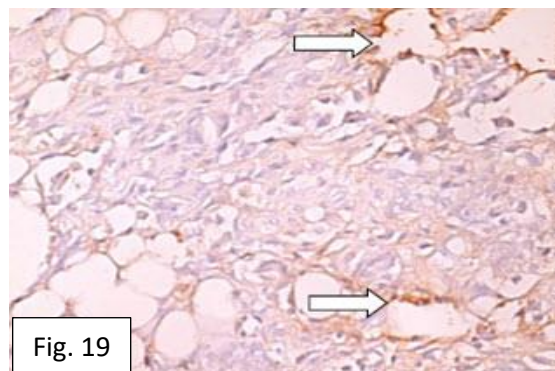




**Fig. (18):** An electron-micrograph of an ultrathin section of sciatic nerve of the injured subgroup B2, 8 weeks after injury, showing the definite myelinated axons (MAX) and unmyelinated axons (UAX). Also notice the formation of collagen fibers (C).

**Uranyl acetate & Lead citrate, X2500**

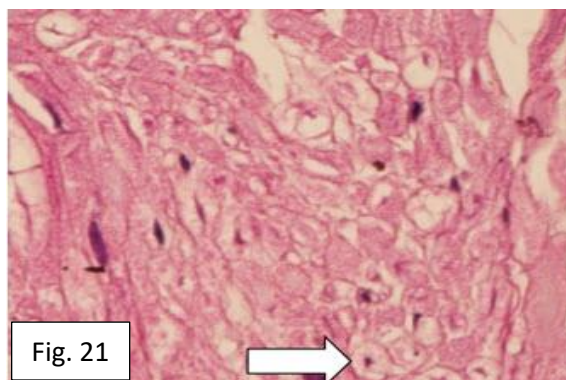
**Fig. (19):** A photomicrograph of transverse section of sciatic nerve of the injured subgroup B2, 8 weeks after injury, showing weak immunoreactivity  $\Rightarrow$  against ED 1 cell **Avidin-biotin technique, x400**

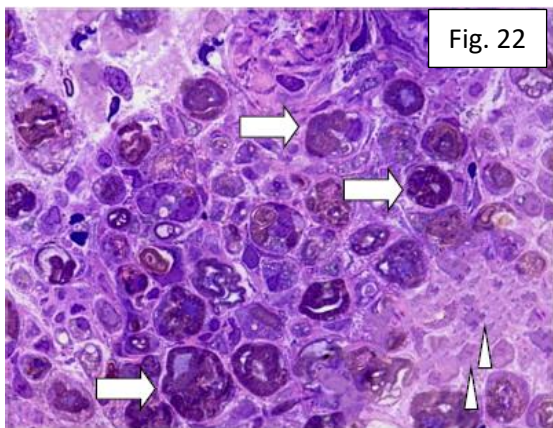


**Fig. (20):** A photomicrograph of transverse section of sciatic nerve of the injured subgroup B2, 8 weeks after injury, showing moderate immunoreactivity to S- 100 antigen.

**Avidin-biotin technique, x400**

**Fig. (21):** A photomicrograph of transverse section of sciatic nerve of the treated subgroup C2, 8 weeks after injury showing the appearance of the well observed axons  $\Rightarrow$ . **Hx. & E., X400**



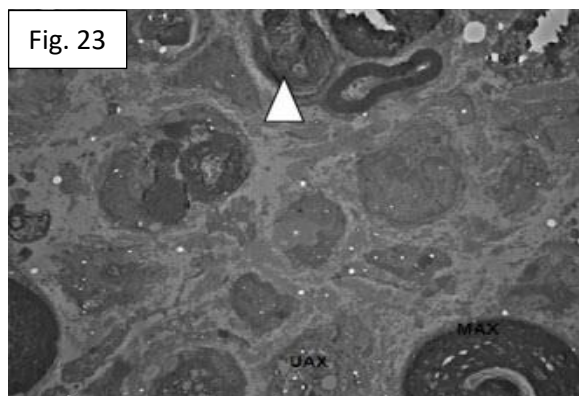


**Fig. (22):** A photomicrograph of transverse section of sciatic nerve of the treated subgroup C2, 8 weeks after injury, showing appearance of myelinating axons  $\Delta$  and unmyelinated axons  $\Rightarrow$  .

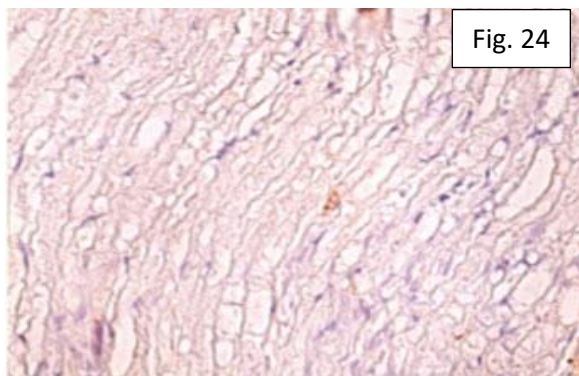
**Toluidine blue, X1000**

**Fig. (23):** An electron-micrograph of an ultrathin section of sciatic nerve of the treated subgroup, C2, 8 weeks after injury, showing the appearance of axons with their myelin sheath (MAX) and the unmyelinated axons (UAX). Notice the presence Schmidt-Lanterman cleft  $\Delta$

**Uranyl acetate & Lead citrate, X2500**

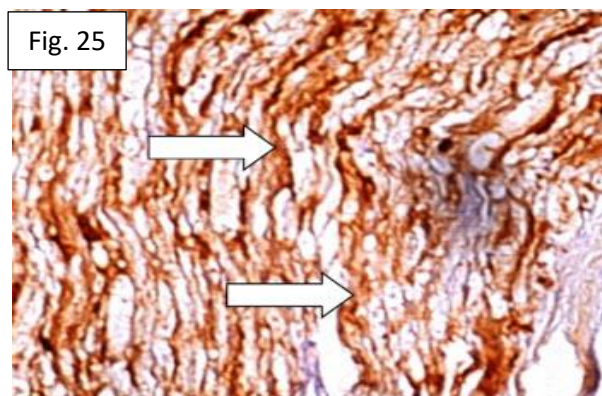


**Fig. (24):** A photomicrograph of transverse section of sciatic nerve of the treated group C2, 8 weeks after injury, showing no immunoreactivity against ED1 cells. **Avidin-biotin technique, x400**



**Fig. (25):** A photomicrograph of transverse section of sciatic nerve of the treated group C2, 8 weeks after injury, showing strong immunoreactivity to S- 100 antigen.

**Avidin-biotin technique, x400**



**Statistical Results:**

As the regenerating axons appeared during the first week and completion of myelination occurred at the 8<sup>th</sup> weeks

therefore the counting was done at the first week and the detection of myelination was at the 8<sup>th</sup> weeks by S-100 antigen reactivity.

**1. Number of regenerating axons in semithin sections:**

There was statistically highly significant increase of the number of the regenerating

axons in the treated subgroup C2 after 8 weeks of the injury with  $P \leq 0.001$  as compared with the injured subgroup B2 as shown in **table (1)**.

Table (1): Number of the regenerating axons 8 weeks after the injury /microscopic field.

Group	Mean	Standard deviation	P value
Sham	210	5.34	
Injured (subgroup B2)	100.5	3.08	
Treated (subgroup C2)	148.16	9.2	0.0003

**2. S-100 antigen immunoreactivity:**

There was highly significant decrease in the immunoreactivity of the area percent in the injured subgroup B1 in comparison with the sham operated control group after one

week with P value  $\leq 0.00003$  and highly significant increase in the immunoreactivity in the treated subgroup C1 in comparison with injured subgroup B1 with P value  $\leq 0.001$  as shown **table (2)**.

Table (2): S-100 immunoreactivity of area percent 1 week after the injury.

Group	Mean	Standard deviation	P value
Sham	0.58%	0.028	
Injured (subgroup B1)	0.19%	0.122	0.0003
Treated (subgroup C1)	0.34%	0.0116	0.0003

**DISCUSSION:**

The present study was designed to evaluate the role of tumour necrosis factor alpha inhibitor (Etanercept) on the regeneration of injured sciatic nerve. Induced sciatic nerve injury followed by immediate treatment with tumour necrosis factor inhibitor revealed alteration of the histological findings on the regeneration process. The histological findings were detected by haematoxylin and eosin stain, toluidine blue stained semithin sections and ultrathin sections. These findings were confirmed by immunoreactivity for both anti ED1 cells for the macrophage cells and S - 100 antigen for Schwann cells.

Rat model of induced sciatic nerve injury and treated groups was adopted by several previous investigators <sup>(13,14)</sup>.

Male rats were chosen to avoid sex hormone fluctuation which could affect the regeneration process <sup>(15)</sup>.

In the present study the effect of the tumour necrosis factor inhibitor in enhancing nerve regeneration was detected in subgroup C1 after one week. Induced sciatic nerve injury on rat was previously done with subsequent treatment with the same drug, however its effect was detected on early stages of Wallerian degeneration over a period of five days <sup>(9)</sup>. The present study was extended over a period of 8 weeks as this period was adopted to be essential for complete regeneration <sup>(16)</sup>.

In the present work, one week after the injury of the sciatic nerve, excessive invasion of macrophage cells was noticed resulting in phagocytosing the myelin sheath and forming myelin debris. Strong immunoreactivity against ED1 cell was expressed after one week. Reaction to S-100 antigen became weak on day 7 due to excessive demyelination and that agreed with the results of **Hung et al** <sup>(17)</sup>.

In the present study, it was noticed that the treated subgroups C1 & C2 showed more immunoreactivity to S-100 antigen in comparison to the injured subgroups B1 & B2.

In the present study, the presence of the regenerating myelinated and unmyelinated axons in the injured and the treated groups were detected. However, the number of the axons in subgroup C1 were noticed to be decreased in comparison to those of the treated subgroup C2. Similar results were mentioned previously<sup>(18)</sup>.

Again, the presence of collagen fibers in ultrathin sections was noticed in group C2 and that agreed with the results of **Jessen and Mirsky**<sup>(19)</sup>.

It was suggested that tumour necrosis factor- $\alpha$  had an important role in regeneration and repair of the peripheral nerves<sup>(18)</sup>. However, tumour necrosis factor- $\alpha$  behaved as initiator to the Wallerian degeneration by activation of the resident Schwann cells and recruitment of the macrophage to the injury site<sup>(18,20)</sup>.

It was observed that autoreactive T cells and macrophages induced secretion of TNF- $\alpha$  which is responsible for immune-mediated neuropathies. The pathogenesis of tumour necrosis factor- $\alpha$  -associated neuropathies included both T-cell and humoral immune response against peripheral nerve myelin, blood vessels induced nerve ischemia and inhibition of signalling for axons repair<sup>(21)</sup>. That was explained as the tumour necrosis factor- $\alpha$  mediated rapid activation of injury by binding of the nuclear factor (NF)- $\kappa$ B to DNA in Schwann cells which is associated with inhibition of axonal sprouting after the injury<sup>(22)</sup>.

Tumour necrosis factor- $\alpha$  existed in two active forms, transmembrane and soluble tumour necrosis factor which differed in expression profiles, ligand affinity, cytoplasmic tail structure and downstream signalling pathway activation<sup>(23)</sup>. The cellular

functions of tumour necrosis factor- $\alpha$  were done by tumour necrosis factor receptor 1 (TNFR1) and TNF receptor 2 (TNFR2). TNFR1, contained a death domain (DD) localized within the cytoplasmic segment that mediated apoptosis and chronic inflammation<sup>(24)</sup>. In addition, TNFR2 was important for cell survival, resolution of inflammation and maintenance of immunity to pathogens as well as the myelination process<sup>(25)</sup>.

It was stated that tumour necrosis factor- $\alpha$  regulates the immune system response as well as the T-cell-mediated tissue injury<sup>(26)</sup>. In contrast, **Kato et al.**, had two studies in 2009 and 2010 reported that antitumour necrosis factor- $\alpha$  prevent nerve degeneration and promote nerve regeneration with restoration of the motor and sensory functions<sup>(27,9)</sup>.

In the present study inhibition of TNF- $\alpha$  was done by using Etanercept. It acted as a competitive inhibitor for tumour necrosis factor- $\alpha$ <sup>(28)</sup>. In addition, tumour necrosis factor- $\alpha$  inhibitor reduces infiltration of macrophages by recruiting myeloid-related proteins 8 and 14 from the peripheral circulation<sup>(29)</sup>.

In the present study immediate administration of anti-tumour necrosis factor- $\alpha$  enhanced axonal regeneration after sciatic nerve injury. Similar findings were previously reported<sup>(9)</sup>.

Despite these reports of favourable effects with the use of anti-TNF- $\alpha$  drugs on peripheral nerve disorders, Etanercept might have side effects on patients with peripheral neuropathies and suggested rare associations between implementation of anti-tumour necrosis factor- $\alpha$  treatment and onset and progression of peripheral nerve disorders such as Guillain-Barré syndrome, Miller Fisher syndrome, and chronic inflammatory demyelinating polyneuropathy<sup>(21)</sup>. However, it was observed that most of these neuropathies improved over a period of months after withdrawal of the TNF- $\alpha$

antagonist, with or without additional immunomodulatory treatment<sup>(30)</sup>.

### Conclusion:

The present work studied the microscopic effect of tumour necrosis factor inhibitor (Etanercept) on the regeneration process of the injured sciatic nerve. It was concluded that its immediate administration after induction of sciatic nerve injury, enhanced the regeneration. This was approved statistically as the number of the regenerating axons in the treated group after 8 weeks showed a highly significant increase than that of the injured group.

### Conflict of interest:

The authors report no conflict of interest.

### Recommendation:

Further studies with longer duration for the effects of tumour necrosis factor inhibitors on injured nerves are recommended.

---

### REFERENCES:

- 1- Pellegatta M. & Taveggia C. (2019): The Complex Work of Proteases and Secretases in Wallerian Degeneration: Beyond Neuregulin-1. *Front. Cell. Neurosci.* <https://doi.org/10.3389/fncel.2019.00093>.
- 2- Shamash, S., Reichert, F. and Rotshenker, S. (2002): The cytokine network of Wallerian degeneration: tumor necrosis factor-alpha, interleukin-1alpha, and interleukin-1beta. *J Neurosci.*, 22:3052–60.
- 3- Wang Y., Guo L., Xihui Yin, and Maureen A. Su (2022): Pathogenic TNF- $\alpha$  drives peripheral nerve inflammation in an Aire-deficient model of autoimmunity, *PNAS* 119 (4) e2114406119.
- 4- Fenrich K. and Gordon, T. (2004): Axonal Regeneration in the Peripheral and Central Nervous Systems - Current Issues and Advances. *Canadian J Neuro Sci.*, 31(2): 142-156.
- 5- Makwana, M. and Raivich, G. (2005): Molecular mechanisms in successful peripheral regeneration. *Febs J.*, 272:2628–38.
- 6- Peppel K, Poltorak A, Melhado I, Jirik F, Beutler B. (1993): Expression of a TNF inhibitor in transgenic mice. *J.Immunol.*, 151(10):5699-703.
- 7- Braun J, McHugh N, Singh A, Wajdula JS, Sato R (2007): Improvement in patient-reported outcomes for patients with ankylosing spondylitis treated with etanercept 50 mg once-weekly and 25 mg twice weekly. *Rheumatology (Oxford)*; 46(6): 999–1004.
- 8- Wenjie S., Sun C, Zhao H, Lin H, Han Q, Wang J, MaH, Chen B, Xiao Z, Dai J. (2009): Improvement of sciatic nerve regeneration using laminin-binding human NGF-beta. *PLoS One.*;4(7): e6180.
- 9- Kato K, Liu H, Kikuchi S, Myers RR, Shubayev VI (2010): Immediate anti-tumor necrosis factor-alpha (etanercept) therapy enhances axonal regeneration after sciatic nerve crush. *J Neurosci Res*; 88: 360–368.
- 10- Gamble M and Bancroft JD. (2008). *Theory and practice of histological techniques*. 6th ed. London. Churchill Livingstone; 121–135.
- 11- Suvarna SK, Layton C and Bancroft JD (2013): *Bancroft's theory and practice of histological techniques*. 7th ed. Churchill Livingstone. Elsevier.; 224, 408-411.
- 12- Sawilowsky s.s.(2005): misconceptions leading to choosing the choosing the test over the Wilcoxon mann- whitney U test for shift in location parameter. *Journal of modern applied statistical methods*,4(2):598-600.
- 13- Que J, Cao Q, Sui T, Du S, Kong D, Cao X. (2013): Effect of FK506 in reducing scar formation by inducing fibroblast apoptosis after sciatic nerve injury in rats *Cell Death Dis.*; 4(3): e526.
- 14- Chen Yu, Xiao-Xu Wang and Jian Qin (2022): Effect of necrostatin-1 on sciatic nerve crush injury in rat models. *Research Square* 2022 | ISSN 2693-5015.

- 15- Muye Zhu & Roberta Diaz Brinton (2012): How Progesterone, a Synthetic Female Hormone, Could Affect the Brain. Available at <http://www.theatlantic.com/author/muye-zhuroberta-diaz-brinton>
- 16- Tanaka K and Webster H (1991): Myelinated fiber regeneration after crush injury is retarded in sciatic nerves of aging mice. *J Comp Neurol* 308: 180-187.
- 17- Hung-Chuan Pan, Yang DY, Ho SP, Sheu ML, Chen CJ, Hwang SM, Chang MH, Cheng FC. (2009): Escalated regeneration in sciatic nerve crush injury by the combined therapy of human amniotic fluid mesenchymal stem cells and fermented soybean extracts, *Natto J Biomed Sciv.*16(1);75.
- 18- Jessen K. R. and Mirsky R. (2019): The Success and Failure of the Schwann Cell Response to Nerve Injury, *Front. Cell. Neurosci.*, 11 February, Sec. Cellular Neuropathology <https://doi.org/10.3389/fncel.2019.00033>
- 19- Murata Y1, Rydevik B, Takahashi K, Takahashi I, Olmarker K. (2004): Macrophage appearance in the epineurium and endoneurium of dorsal root ganglion exposed nucleus pulposus. *J Peripher Nerv Syst.*; 9:158–164.
- 20- Myers RR, Campana WM, Shubayev VI. (2006): The role of neuroinflammation in neuropathic pain: mechanisms and therapeutic targets. *Drug Discov Today* 11:8–20.
- 21- Stubgen JP (2008): Tumour necrosis factor-alpha antagonists and neuropathy. *Muscle Nerve*;37: 281–292.
- 22- Smith KJ and Skelton HG (2001): Rapid onset of cutaneous squamous cell carcinoma in patients with rheumatoid arthritis after starting tumor necrosis factor alpha receptor IgG1-Fc fusion complex therapy". *J. Am. Acad. Dermatol.*; 45 (6): 953–6.
- 23- Gough P. and Myles A. (2020): Tumor Necrosis Factor Receptors: Pleiotropic Signaling Complexes and Their Differential Effects. *Front Immunol.* 2020; 11: 585880. Published online 2020 Nov 25. doi: 10.3389/fimmu.2020.585880
- 24- Holtmann MH, Neurath MF.(2004): Differential TNF signaling in chronic inflammatory disorders. *Curr Mol Med.*; 4:439–44.
- 25- Ierna MX, Scales HE, Mueller C, Lawrence CE.(2009): Transmembrane tumor necrosis factor alpha is required for enteropathy and is sufficient to promote parasite expulsion in gastrointestinal helminth infection. *Infect Immun.*; 77:3879–85.
- 26- Katsuyuki Iwatsuki, Arai T, Ota H, Kato S, Natsume T, Kurimoto S, Yamamoto M, Hirata H. (2013): Targeting Anti-Inflammatory Treatment Can Ameliorate Injury-Induced Neuropathic Pain *PLoS One.*; 8(2): e57721.
- 27- Kato K, Kikuchi S, Shubayev VI, Myers RR (2009): Distribution and tumor necrosis factor-alpha isoform binding specificity of locally administered etanercept into injured and uninjured rat sciatic nerve. *Neuroscience*; 160: 492–500.
- 28- Mohler KM, Torrance DS, Smith CA et al (1993): Soluble tumor necrosis factor (TNF) receptors are effective therapeutic agents in lethal endotoxemia and function simultaneously as both TNF carriers and TNF antagonists. *J Immunol*; 151:1548–1561.
- 29- Rycke L, Basten D, Foell D (2005): Differential expression and response to anti-TNF alpha treatment of infiltrating versus resident tissue macrophage subset in autoimmune arthritis. *J Pathol.*;206:17–27.
- 30- Alsheklee A, Basiri K, Miles JD, Ahmad SA, Katirji B (2010): Chronic inflammatory demyelinating polyneuropathy associated with tumor necrosis factor-alpha antagonists. *Muscle Nerve*;41: 723– 727.

## تأثير مثبت عامل تآكل الورم على تجدد العصب الوريكي المتلف على المدى القصير والطويل في الفأر الأبيض

اشرف محمد صادق (1)، نوال فؤاد رزق الله (1)، حسام محمد الحسيني (2)، هدى محمد مصطفى (1)، جورج فايق حنا (1)، محمد مصطفى فاضل سنبل (1) قسم التشريخ وعلم الأجنة، كلية الطب، جامعه عين شمس (1)

قسم جراحه المخ والأعصاب، كلية الطب، جامعه عين شمس (2)

**المقدمة:** على الرغم من إمكانية التجدد في الجهاز العصبي الطرفي، فإن الاصابات العصبية الشديدة تؤدي إلى فقدان التوصيل العصبي للعضو المستهدف، مما يجعل التحسن الوظيفي الكامل يمثل تحدياً.

**الهدف:** التحقيق من تأثير مثبت عامل تآكل الورم على تجدد العصب الوريكي المتلف على المدى القصير والطويل في الفئران البيضاء.

المواد والطرق المستخدمة: تم استخدام ستة وثلاثون من ذكور الفئران البيضاء البالغين التي قسمت إلى ثلاث مجموعات كل مجموعة اثني عشر فأراً. المجموعة (A) تم استخدامهم كمجموعة ضابطة، المجموعة الفرعية A1 تركت بلا تدخل، المجموعة الفرعية A2 (sham)، تم التضحية بنصف الفئران من المجموعتين في الاسبوع الأول و النصف الآخر في الاسبوع الثامن، المجموعة B (المجموعة المصابة) تم تقسيمها الي مجموعتين وتم عمل قطع للعصب الوريكي لهم ثم تم ترقيع العصب وتوصيل نهاية الأطراف، تمت التضحية بالفئران بعد أسبوع B1 ثم بعد ثماني أسابيع B2. المجموعة C (المجموعة المعالجة) تم تقسيمها الي مجموعتين وتم إحداث قطع للعصب الوريكي لهم ثم ترقيع العصب وتوصيل لنهاية الاطراف. وبعد ذلك تم حقنهم بمثبط عامل تآكل الورم داخل التجويف البروتوني بجرعة تم حسابها على اساس 6 مجم لكل كجم من وزن الفأر. تمت تلك العملية بعد أسبوع C1 ثم بعد ثماني اسابيع بعد الإصابة C2, اخذت عينة من الأعصاب لكل المجاميع وتم تجهيزها للفحص باستخدام المجهر الضوئي وكذلك بالمجهري الإلكتروني النافذ وايضا استخدام مواضع التوطن المناعي كطرق تأكيدية للبحث. قد تم تحليل النتائج باستخدام تقنيات تحليل الصور وإجراء التحليل الإحصائي.

**النتائج:** كشف هذا البحث على أن اعطاء مثبت عامل تآكل الورم فور عمل الإصابة للعصب الوريكي ادي الي العديد من التعديلات النسيجية في عملية التجديد. عند فحص العينة بعد أسبوع واحد من احداث الإصابة للعصب لوحظ وجود متزايد للخلايا البالعة في مكان الإصابة في المجموعة المصابة. كذلك وضحت زيادة في مواضع التوطن للأجسام المضادة ED 1 الموجودة في سيتوبلازم الخلايا البالعة. عند فحص العينة بعد ثمانية اسابيع ازدادت اعداد المحاور العصبية المتجددة وكانت مواضع التوطن للأجسام المضادة S 100 -في المجموعة المعالجة إحصائياً أكثر من مثيلاتها في المجموعة المصابة.

**الخلاصة:** أظهرت هذه الدراسة أن مثبت عامل تآكل الورم كان له تأثير واضح على عملية التجديد العصبي وذلك من خلال تقليل دخول الخلايا البالعة. ويتضح ان تعديل التفاعل التهابي يعزز تجديد الأعصاب الطرفية.